

High PSMA expression is associated with immunosuppressive tumor microenvironment in clear cell renal cell carcinoma

Panagiotis J. Vlachostergios^{1,2,3,*}, Athanasios Karathanasis,² Konstantinos Dimitropoulos,⁴ Ioannis Zachos,² Vassilios Tzortzis²

¹Department of Medical Oncology, IASO Thessaly Hospital, Larissa 41110, Greece

²Department of Urology, University of Thessaly, School of Health Sciences, Faculty of Medicine, University Hospital of Larissa, Larissa 41110, Greece

³Division of Hematology and Medical Oncology, Department of Medicine, Weill Cornell Medicine, New York, NY 10065, USA

⁴Department of Urology, Aberdeen Royal Infirmary, Aberdeen AB252ZN, UK

*Corresponding author: Panagiotis J. Vlachostergios, pjv9003@med.cornell.edu

Dear Editor,

Clear cell renal cell carcinoma (ccRCC) is a highly vascular tumor. Among surrogate markers that may reflect the neovascular burden of ccRCC, prostate specific membrane antigen (PSMA) has emerged as a promising one, by virtue of its ability to be measured either immunohistochemically and transcriptionally or on positron emission tomography (PET) imaging [1, 2]. While the relationship between PSMA and neoangiogenesis in ccRCC is well established, the potential association between PSMA and the immune landscape of ccRCC is much less understood.

Our study aimed to investigate whether PSMA expression at transcript (*FOLH1* gene) and protein levels is associated with immune activation or evasion signals in ccRCC. A publicly available database, cBioportal for Cancer Genomics (www.cbioportal.org), was used to query RNA sequencing and immunohistochemical data for *FOLH1* mRNA and protein expression respectively, in a prospective multicenter cohort of 512 patients with ccRCC (see online supplementary material).

A total of 241 patients (47%) had tumors with altered *FOLH1*, predominantly high mRNA and protein expression ($n = 211$, 41%) (Fig. 1A). We then examined whether *FOLH1* expression at mRNA and protein levels in ccRCC patients was associated with clinical or/and pathological parameters. Patient subgroups with high *FOLH1* vs unaltered tumors were equally distributed with respect to age, sex, and ethnicity (supplementary Fig. 1A, see online supplementary material). *FOLH1*-overexpressing tumors were associated with higher T-stage ($P = 0.025$), particularly T3a and T3b, compared to unaltered ones (22% and 9% vs 25% and 12%, respectively) (Fig. 1B). Tumors with high *FOLH1* had proportionally, but not significantly higher histologic grade ($P = 0.846$), particularly grade 3 (40% vs 38%) and grade 4 (16% vs 14%), lymph node involvement (25% vs 24%, $P = 0.877$), and more advanced clinical stage (IV 18% vs 14%, $P = 0.611$) (supplementary Fig. 1B).

We then sought to determine whether elevated *FOLH1* transcript and protein levels had a favorable or negative impact on survival without disease recurrence/progression and on overall survival. Corresponding patients with high somatic PSMA expression experienced a shorter progression-free survival (88 months vs not-reached, log-rank $P = 0.014$). There was also a non-significant

trend towards a shorter overall survival (80 vs 89 months, log-rank $P = 0.899$) (Fig. 1C).

To investigate the clinical implication of PSMA in angiogenic signaling of ccRCC patients, we assessed for correlations of *FOLH1* expression with angiogenesis genes. *FOLH1* mRNA expression was directly associated with the most important genes activated during angiogenesis, including *VEGFA*, *FLT1*, *HIF1A*, and *EPAS1* ($P < 0.001$) (Fig. 1D). Because angiogenesis and immunosuppression work hand-in-hand in ccRCC development and progression, this study sought to determine whether *FOLH1*-overexpression could be associated with expression of key immune checkpoints and immune activation genes that are involved in the promotion of an immunosuppressive tumor microenvironment. Indeed, *CD274* ($P = 0.017$), and *PDCD1*, *CTLA4*, *LAG3*, *CD8A*, and *IFNG* expression ($P < 0.001$ respectively) was significantly suppressed in *FOLH1*-overexpressing ccRCC tumors compared to non-altered ones (Fig. 1E, and supplementary Table 1, see online supplementary material).

Collectively, this study investigated PSMA expression at transcriptional and protein levels in a large cohort of patients with ccRCC. First, PSMA and its encoding gene *FOLH1* were found to be altered in almost half of ccRCC tumors, the vast majority of which (211/241 or 88%) displayed upregulated mRNA expression. These patients were characterized by larger, less differentiated primary tumors and were more likely to present with, or/and experience, progression to advanced/recurrent disease, respectively. Second, *FOLH1*-overexpressing tumors were characterized by an active angiogenesis transcriptional program driven by *VEGFA*, *FLT1*, *HIF1A*, and *EPAS1* overexpression, concurrent with an immunosuppressive microenvironment evidence by downregulation of expression of most important immune checkpoints, including *CD274*, *PDCD1*, *CTLA4*, and *LAG3*, as well as suppression of immune-activation signals including *CD8A* and *IFNG*.

The prognostic role of PSMA has been previously inconsistently reported by other groups [1, 3]. This comprehensive study in the largest available TCGA ccRCC cohort to date establishes the value of PSMA protein and *FOLH1* mRNA measurement in predicting progressive disease in these patients. It is also in line with recent efforts to more accurately stage localized ccRCC as well as visualize early recurrent disease via PSMA-PET imaging. PSMA

Received 4 February 2024; accepted 15 April 2024; published 16 April 2024

© The Author(s) 2024. Published by Oxford University Press on behalf of the West China School of Medicine & West China Hospital of Sichuan University. This is an Open Access article distributed under the terms of the Creative Commons Attribution-NonCommercial License (<https://creativecommons.org/licenses/by-nc/4.0/>), which permits non-commercial re-use, distribution, and reproduction in any medium, provided the original work is properly cited. For commercial re-use, please contact journals.permissions@oup.com

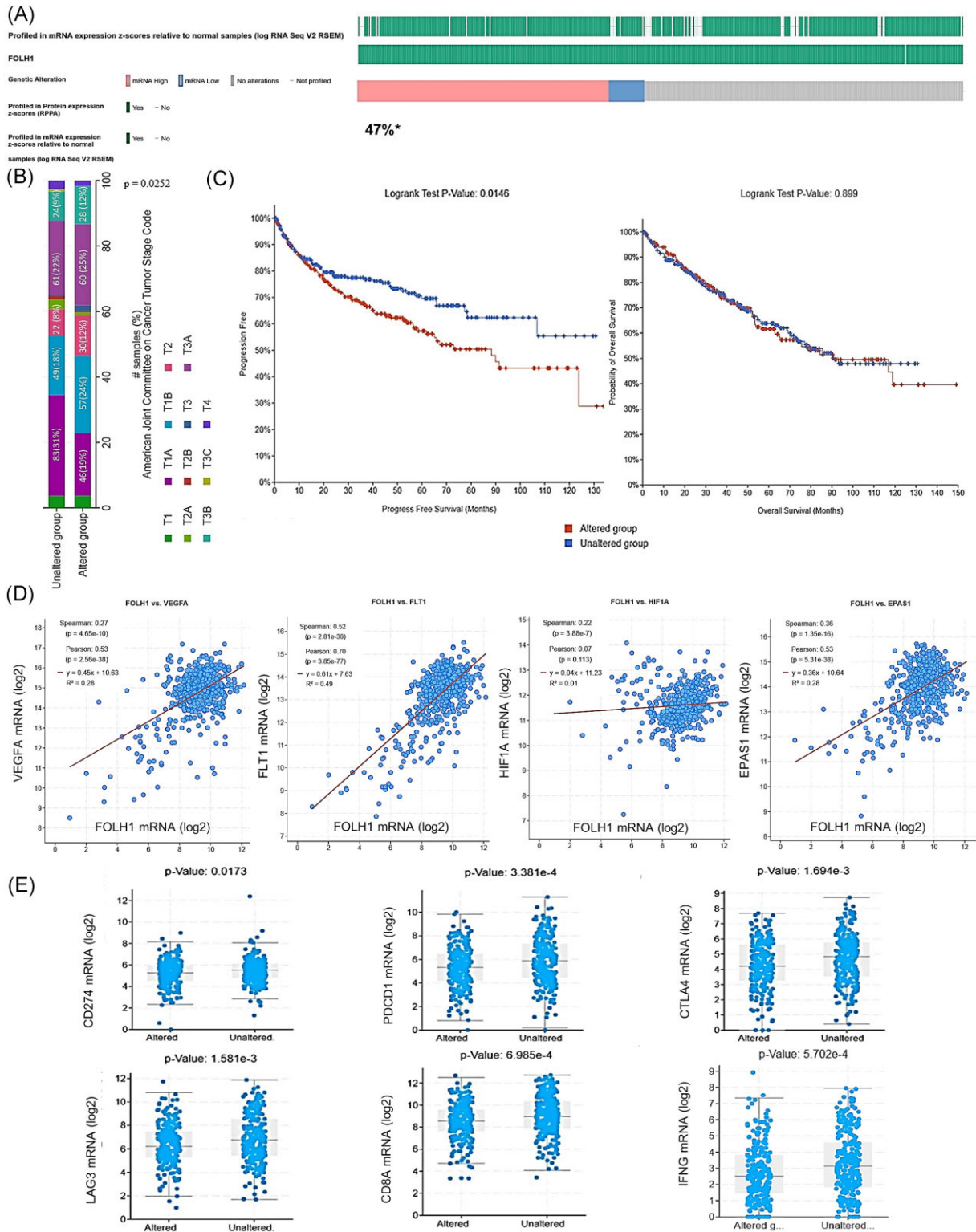


Figure 1. (A) Oncoplot of FOLH1 mRNA and protein expression in the TCGA ccRCC cohort (n = 512). *Altered/profiled: 241/511. (B) Distribution of pathologic T-stage among patients with FOLH1-altered (predominantly high) and unaltered tumors, compared to normal tissue. #Number of samples (%). (C) Kaplan-Meier plots for progression-free survival and overall survival in ccRCC patients from the TCGA cohort (n = 512). (D) mRNA log₂ expression of angiogenesis genes VEGFA, FLT1, HIF1A, and EPAS1 in association with FOLH1 expression. (E) mRNA log₂ expression of immune genes CD274, PDCD1, CTLA4, LAG3, CD8A, and IFNG in association with FOLH1 expression.

immunoreactivity is detectable only in the tumor-associated vessels and not in tumor cells, with staining intensity being the strongest and most diffuse in ccRCC, compared to the RCC subtypes [4]. Standardized uptake value maximum (SUVmax) of RCC on 68 Ga-PSMA-11 PET/CT has not only correlated with immunohistochemical tissue PSMA staining, but also resulted in changes in clinical management of more than one-third of patients because of the discovery of new metastases not detected with conventional imaging [5, 6]. These results indicate that PSMA could become a key biomarker with the ability to guide definitive vs palliative treatment selection. Taking a step further, PSMA uptake may also be useful in the assessment of early response and sensitivity to anti-angiogenic and immune checkpoint inhibitor therapies in patients with metastatic disease [7].

PSMA uptake on gallium-prostate specific membrane antigen-11 positron emission tomography/computed tomography (Ga-PSMA-11 PET/CT) was shown to directly correlate with immunohistochemical vascular endothelial growth factor receptor 2 (VEGFR-2)/platelet-derived growth factor receptor β (PDGFR- β) as well as with hypoxia-inducible factor 2 α (HIF-2 α) expression in primary RCC tumors [8, 9]. Our study supports these findings and provides the biological rationale for these clinical correlations since FOLH1-overexpressing tumors were characterized by increased expression of genes encoding these pro-angiogenic signals, including VEGFA encoding the dominant inducer of blood vessel growth; and FLT1 encoding VEGFR1, a receptor tyrosine kinase which is activated by VEGF-A, VEGF-B, and placental growth factor and the two main hypoxia-responsive genes that are key players in angiogenesis, HIF1A, and EPAS1. Particularly in view of recent advances in therapeutic targeting of resistant ccRCC tumors, using PSMA as a surrogate of tissue HIF-2 α expression in primary tumors or/and metastases could have great potential in predicting responses to HIF-2 α antagonists such as belzutifan.

Our study demonstrates for the first time that PSMA-overexpressing tumors are immune depleted, evidenced by low mRNA expression of key immune checkpoints CD274, encoding PD-L1, PDCD1 encoding PD-1, CTLA4, and LAG3. Downregulation of important immune signals involved in immune activation and processing, such as CD8A and IFNG further supports the notion that PSMA participates in the formulation of an immunosuppressive microenvironment. The fact that these immune checkpoints are druggable with monoclonal antibodies that are either in current use for ccRCC or in clinical trials indicates the potential of PSMA detection in tissue or/and imaging as a surrogate of resistance to such therapies, which may help with selection of mRCC patients suitable for combination or alternative treatment approaches. PSMA involvement in immune evasion of ccRCC is further supported by recent data showing that tumors with higher radiographic uptake of the PSMA ligand on 68Ga-PSMA-11 PET/CT are characterized by PBRM1 deficiency, which is associated with infiltration from exhausted T-cells [10].

Our study was limited by its computational design and single-cohort evaluation, which is however, the largest reported to date with both molecular and survival data available. Additionally, the key immune checkpoints and immune signals were evaluated on bulk-RNA seq level, which could limit the clinical significance of the study. Nevertheless, this work represents a comprehensive effort to study the molecular landscape and clinical relevance of PSMA-altered ccRCC, demonstrating a pro-angiogenic, immune-depleted contexture with prognostic significance. Additional studies are needed to further elucidate the immunogenomic profile of PSMA-overexpressing ccRCC, in order to earlier and better diag-

nose, stage, and treat these patients with tailored targeted therapies.

Author contributions

P.J.V.: conceptualization, data curation, methodology, visualization, writing—original draft—review and editing, and supervision. A.K.: data curation, visualization, and writing—original draft. I.Z.: methodology, writing—review and editing. V.T.: writing—review and editing, and supervision. All authors have read and agreed to the published version of the manuscript. All authors were involved in manuscript editing and manuscript review.

Supplementary data

Supplementary data is available at [PCMED](https://www.ncbi.nlm.nih.gov/pmc/articles/PMC1017646861) online.

Conflict of interest

None declared.

Data availability

The data that support the findings of this study are available at https://www.cbiportal.org/study/summary?id=kirc_tcga_pan_can_atlas_2018, accessed on 27 January 2024.

References

- Baccala A, Sercia L, Li J et al. Expression of prostate-specific membrane antigen in tumor-associated neovasculature of renal neoplasms. *Urology* 2007;**70**:385–90. <https://doi.org/10.1016/j.urology.2007.03.025>.
- Muselaers S, Erdem S, Bertolo R et al. PSMA PET/CT in renal cell carcinoma: an overview of current literature. *J Clin Med* 2022;**11**:1829. <https://doi.org/10.3390/jcm11071829>.
- Spatz S, Tolkach Y, Jung K et al. Comprehensive evaluation of prostate specific membrane antigen expression in the vasculature of renal tumors: implications for imaging studies and prognostic role. *J Urol* 2018;**199**:370–7. <https://doi.org/10.1016/j.juro.2017.08.079>.
- Bui VN, Unterrainer LM, Brendel M et al. PSMA-expression is highly associated with histological subtypes of renal cell carcinoma: potential implications for theranostic approaches. *Biomedicines* 2023;**11**:3095. <https://doi.org/10.3390/biomedicines11113095>.
- Li Y, Zheng R, Zhang Y et al. Special issue “the advance of solid tumor research in China”: 68Ga-PSMA-11 PET/CT for evaluating primary and metastatic lesions in different histological subtypes of renal cell carcinoma. *Int J Cancer* 2023;**152**:42–50. <https://doi.org/10.1002/ijc.34189>.
- Raveenthiran S, Esler R, Yaxley J et al. The use of 68Ga-PET/CT PSMA in the staging of primary and suspected recurrent renal cell carcinoma. *Eur J Nucl Med Mol Imaging* 2019;**46**:2280–8. <https://doi.org/10.1007/s00259-019-04432-2>.
- Seront E, Lhommel R, Tombal B. Case report: early 68Ga-PSMA-PET metabolic assessment and response to systemic treatment for first-line metastatic clear cell renal cell carcinoma; about two clinical cases. *Front Oncol* 2021;**11**:782166. <https://doi.org/10.3389/fonc.2021.782166>.
- Gao J, Meng L, Xu Q et al. 68Ga-PSMA-11 PET/CT parameter correlates with pathological VEGFR-2/PDGFR- β expression in renal cell carcinoma patients. *Mol Imaging Biol* 2022;**24**:759–68. <https://doi.org/10.1007/s11307-022-01725-1>.

9. Meng L, Zhang S, Gao J et al. [68Ga]Ga-PSMA-11 PET/CT has potential application in predicting tumor HIF-2 α expression and therapeutic response to HIF-2 α antagonists in patients with RCC. *Eur Radiol* 2022;**32**:6545–53. <https://doi.org/10.1007/s00330-022-08738-y>.
10. Wang B, Deng Y, Xu Q et al. Exploration of 68Ga-labelled prostate-specific membrane antigen-11 PET/CT parameters for identifying PBRM1 status in primary clear cell renal cell carcinoma. *Clin Radiol* 2023;**78**:e417–24. <https://doi.org/10.1016/j.crad.2023.01.003>.