



Late onset ilio-psoas abscess due to stump appendicitis: a case report

Dafer M. Al Shehri¹, Abdullah K. Asiri², Walid M. Abd El Maksoud^{3,✉}

¹General Surgery, Aseer Central Hospital, Abha, Saudi Arabia;

²Faculty of Medicine, King Khalid University, Abha, Saudi Arabia;

³General Surgery, Faculty of Medicine, King Khalid University, Abha, Saudi Arabia.

Abstract

We describe a case of right ilio-psoas abscess caused by stump appendicitis 14 years after open appendectomy. Stump appendicitis is a rare complication of appendectomy. Right ilio-psoas abscess was diagnosed in an immune-competent patient and treated by ultrasound guided percutaneous drainage twice without identifying the cause of the abscess. The patient did not improve until diagnostic laparoscopy was performed revealing a long stump appendicitis to be the origin of infection. It was treated by completion appendectomy. Surgical exploration may be necessary in persistent or recurrent ilio-psoas abscesses. We identified 4 reported cases of post-appendectomy ilio-psoas abscess but without recognizing the cause of the abscess and its relation to appendectomy. This is the first reported case of ilio-psoas abscess that developed as a complication of stump appendicitis.

Keywords: stump appendicitis, iliopsoas abscess, delayed complications, appendectomy

Introduction

Stump appendicitis is an extremely rare complication of appendectomy with a reported incidence of 1 in 50,000 cases^[1–2]. Prompt recognition of stump appendicitis can prevent serious complications such as intra-abdominal abscess^[3–4].

We report a case of late onset ilio-psoas abscess as a complication of long stump appendicitis after appendectomy for perforated appendix 14 years earlier.

Case report

A 39-year-old male patient presented to the emer-

gency department complaining of right lower quadrant abdominal pain, lower back pain radiating to the right thigh, fever, night sweating, loss of appetite, and weight loss for two months. The patient had a history of open appendectomy 14 years earlier for perforated appendix. On physical examination, the abdomen was lax except for right lower quadrant tenderness. A sensation of fullness of the right flank raised the suspicion of an ilio-psoas abscess. Laboratory findings were within normal ranges including a white blood cell count of $9.32 \times 10^3/\mu\text{L}$. Contrast enhanced magnetic resonance imaging (MRI) was carried out which confirmed the diagnosis and revealed a $19 \times 3 \times 7$ cm right retroperitoneal fluid collection extending along the right

✉ Corresponding author: Walid M. Abd El Maksoud, Associate Professor of General Surgery, Faculty of Medicine, King Khalid University, Abha 61421-641, Saudi Arabia. Tel: 00966543128555, Email: dr.waleedmaksoud@gmail.com.

Received 10 December 2016, Revised 25 February 2017, Accepted 8 May 2017, Epub 10 June 2017

CLC number: R687.1, Document code: B

The authors reported no conflict of interests.

This is an open access article under the Creative Commons Attribution (CC BY 4.0) license, which permits others to distribute, remix, adapt and build upon this work, for commercial use, provided the original work is properly cited.

psoas muscle with extension into the upper right iliacus muscle (**Fig. 1**). Ultrasound guided percutaneous drainage was done. The drained fluid was initially purulent and after few days turned serous. Culture and sensitivity testing of pus revealed growth of *Staphylococcus epidermidis*. The patient was tested for tuberculosis, brucellosis, and human immunodeficiency virus infection and all were ruled out. The patient was discharged with the drainage tube in place on cephalexin 500 mg every 12 hours for two weeks. Three weeks later, the drainage tube accidentally slipped away, but the patient had no abdominal symptoms. Follow up computed tomography (CT) scan showed a 65 mm × 22 mm residual collection. Conservative management was advised together with follow up but unfortunately the patient missed his follow up visits.

After ten months, the patient presented again to the emergency room complaining of the same previous symptoms. Contrast enhanced Magnetic Resonance Imaging (MRI) carried out for him and showed right retroperitoneum collection measuring 6 cm × 1.5 cm with residual right psoas and iliacus muscle inflammatory changes (**Fig. 2**) which seemed to be the same previous collection without improvement. Ultrasound-guided percutaneous drainage (PCD) was done. Culture and sensitivity testing of pus revealed growth of staphylococcus epidermidis. Ten days later, follow up Computed tomography images (CT Scan) showed a significant decrease in the residual abscess cavity. The drainage tube was removed and the patient was discharged with a strict plan of follow up.

One year later, the patient presented again with similar symptoms. Contrast enhanced MRI revealed residual inflammatory process at the right psoas and iliacus muscle without significant retroperitoneal collection. Because of persistence of the inflammatory

process despite good drainage and after the radiological studies did not reveal any definite source of infection, diagnostic laparoscopy was done to search for the cause of recurrence which was suggested to be a foreign body. Intraoperatively, there were small bowel adhesions to the wall of the abdomen and pelvis that required adhesiolysis. The right colon was mobilized revealing an inflamed long stump remnant appendix, which was ligated and removed (**Fig. 3**). A biopsy was taken from the unhealthy tissue of the right psoas muscle. Histopathological examination confirmed that the excised tissue was a long stump of the appendix showing signs of inflammation with no evidence of malignancy. Right psoas muscle biopsy showed inflammatory cells and inflammatory exudates. The patient was covered with antibiotics including ciprofloxacin 500 mg/12 hours and metronidazole 500 mg/8 hours. A week later, the patient was discharged and scheduled for follow up appointments. After one year of follow up, the patient was totally free with no new complaints.

Discussion

Ilio-psoas abscess is a rare condition, and usually occurs secondary to local infection or inflammatory process from adjacent structures^[5]. Historically, Ilio-psoas abscess was a well-recognized complication of tuberculosis of the spine. Nowadays primary ilio-psoas abscess is particularly diagnosed in immunocompromised patients, and *Staphylococcus aureus* is the main causative pathogen^[6]. Some conditions such as acute appendicitis, diverticulitis, Crohn's disease, colorectal carcinoma, and rectal trauma can lead to secondary ilio-psoas abscess^[7]. Variable clinical presentation of ilio-psoas abscess delays diagnosis and leads to high morbidity and mortality^[8].

The clinical presentation of our patient was non-

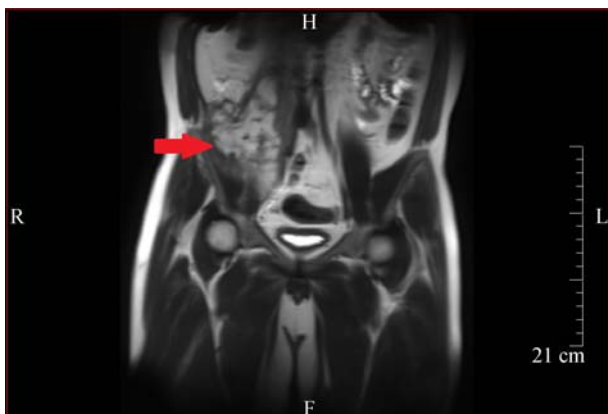

Fig. 1 MRI demonstrates a 19 cm × 3 cm × 7 cm fluid collection (arrow) extending along the right psoas muscle with extension into the upper right iliacus muscle

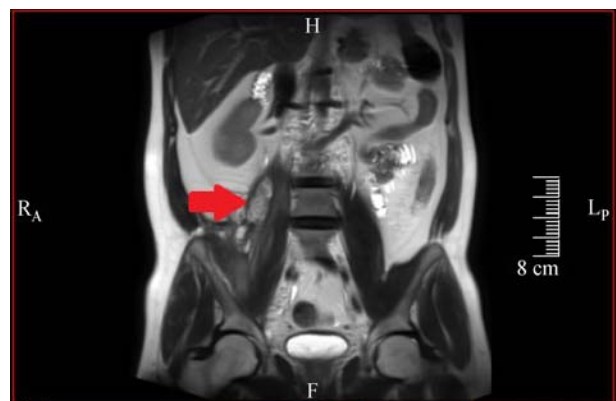


Fig. 2 MRI shows residual right retroperitoneum collection (arrow) measuring 6 cm × 1.5 cm with residual right psoas and iliacus muscle inflammatory changes.

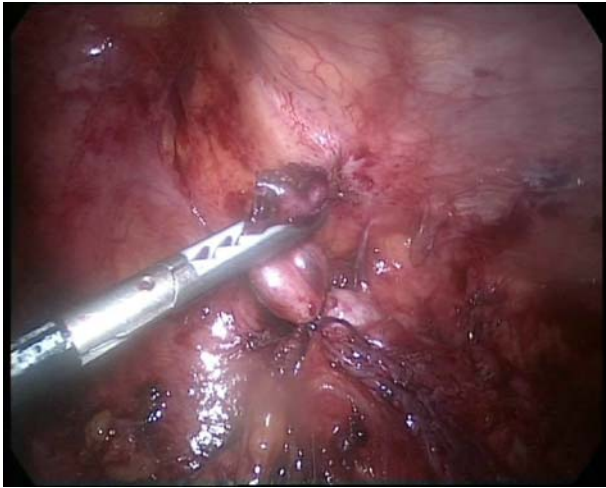

Fig. 3 Long stump remnant appendix which was ligated and removed.

specific to any peculiar condition. Ilio-psoas abscess was clearly identified after performing the abdominal radiological studies for the patient. Furthermore, the patient was found to be free of tuberculosis, without obvious medical condition that can cause ilio-psoas abscess. This, together with failed conservative management, compelled us to search for unusual cause of ilio-psoas abscess, and hence laparoscopic exploration was done.

There are two hypotheses explaining late development of psoas abscess after appendectomy. First, it may be due to the presence of remnant infected tissues as a complication of appendectomy. Another hypothesis presumes a micro-perforation existing as a complication of acute appendicitis which becomes symptomatic later^[6]. In our case, iliopsoas abscess was a result of inflamed long stump appendicitis. This may be considered as a new possible explanation for late development of psoas abscess after appendectomy.

Ultrasonography guided percutaneous drainage is the method of choice for drainage of localized intraabdominal collections as it is efficient, less invasive with low radiation hazards^[9], nevertheless, surgical drainage provides a method to treat an underlying pathology. In our case we started management by percutaneous drainage of the abscess; however, when the patient still complained of the same symptoms, despite good drainage, we suspected the presence of unusual cause to be the primary source of infection. After performing diagnostic laparoscopy for the patient, long stump appendicitis was surprisingly the origin of infection in his condition.

Diagnosis of stump appendicitis is usually difficult because it is an unfamiliar clinical entity. Its late presentations and previous history of appendectomy

decrease suspicion of appendicular diseases. Delayed diagnosis may lead to serious complications such as small bowel obstruction, hemorrhage from the mesoappendix, generalized peritonitis, and intra-abdominal abscess^[4]. Stump appendicitis could be diagnosed radiologically, more specific with abdomen CT scan. The findings are similar to those found in acute appendicitis including cecal wall thickening, pericecal inflammation, abscess formation, and fluid collection in the right paracolic gutter^[1]. Completion appendectomy is the treatment of choice for stump appendicitis, and extensive surgery such as ileocolic resection may be necessary if there is significant inflammation around the ileocecal region^[1,4]. In our case, appendectomy was performed 14 years before the patient's complaints. Stump appendicitis was not mentioned in the MRI or CT reports even after revision. Ultimately, completion appendectomy was performed for our patient and was curative of the condition.

We conducted a PubMed and Google Scholar search for iliopsoas abscess as a complication of stump appendicitis using the keywords "complications of appendectomy", "stump appendicitis", "iliopsoas abscess", and "psoas abscess".

Regardless of the reported cases of retroperitoneal abscess due to acute appendectomy, there are only four cases reported in the literature of late onset retroperitoneal abscess associated with old appendectomy. The first one is a case of left psoas abscess reported in 1989 for a patient operated for appendectomy and a cesarean section more than ten years prior to presentation of psoas abscess^[10]. The second case was reported in 1992 as a case of right psoas muscle abscess presented ten years after appendectomy. The third case was reported in 2010 as a case of retroperitoneal mass for a patient who had interval appendectomy for acute perforated appendicitis two years before presentation. The fourth case reported in 2014 was a case of iliopsoas abscess with history of acute appendicitis and complicated appendectomy four years before presentation of iliopsoas abscess^[6]. Authors of all the above mentioned cases considered the presence of the retroperitoneal abscess as a late uncommon complication of appendicitis without identifying a cause of delayed onset of the abscess or an actual relation between appendicular disease and abscess formation.

In this study, we report the first case of iliopsoas abscess formation after appendectomy proved to be a complication of stump appendicitis.

In conclusion, residual long stump of the appendix after appendectomy might lead to persistence of infection and possibly late complications such as intraperitoneal, retroperitoneal or iliopsoas abscess.

Surgical exploration may be necessary in persistent cases of ilio-psoas abscess, to allow for recognition and treatment of the underlying pathology.

References

- [1] Hendahewa R, Shekhar A, Ratnayake S. The dilemma of stump appendicitis- A case report and literature review[J]. *Int J Surg Case Rep*, 2015, 14: 101–103.
- [2] Jaffe BM, Berger DH. The appendix. Edited by: Brunnicardi FEiC. *Schwartz's Principles of Surgery*[M]. New York: McGraw Hill Companies Inc. 2005.
- [3] Shelton T, McKinlay R, Schwartz RW. Acute appendicitis: current diagnosis and treatment[J]. *Curr Surg*, 2003, 60(5): 502–505.
- [4] Kanona H, Al Samaraee A, Nice C, et al. Stump appendicitis: a review[J]. *Int J Surg*, 2012, 10(9): 425–428.
- [5] Petrovic I, Pecin I, Prutki M, et al. Thigh abscess as an extension of psoas abscess: the first manifestation of perforated appendiceal adenocarcinoma: case report[J]. *Wien Klin Wochenschr*, 2015, 127(15-16): 645–648.
- [6] Moslemi S, Tahamtan M, Hosseini SV. A late-onset psoas abscess formation associated with previous appendectomy: a case report[J]. *Bulletin Emerg & Trauma*, 2014,2(1):55.
- [7] Choi SB, Han HJ, Kim WB, et al. A case of a recurrent iliopsoas abscess masking a complicated appendicitis successfully treated by a laparoscopic approach[J]. *Surg Laparosc Endosc Percutan Tech*, 2010, 20(2): e69–e72.
- [8] Cargill T, Gupta V, Thomas P. Pyogenic iliopsoas abscess: An uncommon presentation of nonspecific leg pain[J]. *J Acute Medicine*, 2014, 4(4): 154–156.
- [9] Dave BR, Kurupati RB, Shah D, et al. Outcome of percutaneous continuous drainage of psoas abscess: A clinically guided technique[J]. *Indian J Orthop*, 2014, 48(1): 67–73.
- [10] Chen YC, Chen ST, Chen YS. Psoas abscess: report of a case [J]. *Taiwan Yi Xue Hui Za Zhi*, 1989, 88: 752–754.