



# Single-incision laparoscopic surgery for pediatric inguinal hernias using an epidural needle: A reliable and simpler operation method

Xin-long Wang<sup>1</sup>, Dan Tian<sup>2</sup>, Jia-he Zhang<sup>1</sup>, Jing Wei<sup>1</sup>, Jin-long Li<sup>1</sup>, Ye Gu<sup>3</sup>

## Abstract

**INTRODUCTION:** Laparoscopic repairs for pediatric inguinal hernia have gained gradual acceptance in the past. The objective of this study was to evaluate the clinical efficacy and significance of single-site laparoscopic percutaneous extraperitoneal closure of the internal ring using an epidural needle for children with inguinal hernia.

**MATERIALS AND METHODS:** We retrospectively analyzed clinical data of 529 children with inguinal hernia who underwent single-site laparoscopic percutaneous extraperitoneal closure of the internal ring using an epidural needle at our hospital from January 2019 to August 2024.

**RESULTS:** All micro-laparoscopic surgeries were successfully performed in the 529 patients, among them, a contralateral patent processus vaginalis was present in 208 patients with unilateral pathology and thus simultaneously repaired; a total of 737 cases of inguinal hernia were repaired. The average operating time was  $13.42 \pm 4.42$  min for unilateral hernioplasty and  $19.20 \pm 2.49$  min for bilateral hernioplasty. Only one male patient experienced a recurrence that required reoperation. In terms of postoperative complications, there were no surgical site infections, testicular atrophy, or abdominal adhesions. The mean follow-up time was  $14.12 \pm 3.45$  months. All the patients had a small operative scar, which was minimally visible.

**CONCLUSION:** Single-port laparoscopic surgery using an epidural needle for children is a technically straightforward and reliable approach for treating pediatric inguinal hernias, characterized by high applicability, minimal postoperative complications, reduced recurrence risk, rapid convalescence, and superior aesthetic outcomes.

## Keywords:

Double-line band method, pediatric inguinal hernia, single-port laparoscopic surgery

## Introduction

Inguinal hernia is one of the most prevalent complications in pediatric surgery, with an incidence range of 0.8%–4.4%.<sup>[1]</sup> Due to the risk of organ incarceration and necrosis, surgery is usually recommended once an inguinal hernia is diagnosed. With its technical advantages, laparoscopic surgery has gradually become the preferred surgical

method for surgeons. Several benefits have been reported for the laparoscopic repair in children, including reduced tissue trauma, comparable recurrence rates, and faster recovery times, compared to the traditional open method.<sup>[2,3]</sup> To optimize cosmetic outcomes and simplify the procedure, some surgeons have attempted to enlarge the umbilical port and have solely utilized an assistant forceps for the operation.<sup>[4,5]</sup> However, this increases the trauma and exacerbates the postoperative discomfort, while the proximity of the

This is an open access article distributed under the terms of the Creative Commons Attribution-NonCommercial-NoDerivatives 4.0 License (CC BY-NC-ND), where it is permissible to download and share the work provided it is properly cited. The work cannot be changed in any way or used commercially without permission from the journal.

For reprints contact: WKHLRPMedknow\_reprints@wolterskluwer.com

**How to cite this article:** Wang X-l, Tian D, Zhang J-h, Wei J, Li J-l, Gu Y. Single-incision laparoscopic surgery for pediatric inguinal hernias using an epidural needle: A reliable and simpler operation method. *Int J Abdom Wall Hernia Surg* 2025;8:254-60.

<sup>1</sup>Department of Gastrointestinal Surgery,  
<sup>2</sup>Department of Anesthesiology,  
<sup>3</sup>Department of Pediatric Surgery, The Second Hospital of Jilin University, Changchun, China

## Address for correspondence:

Prof. Jin-long Li,  
Department of Gastrointestinal Surgery, The Second Hospital of Jilin University, Nangan District, Changchun 130041, China.  
E-mail: jinlong@jlu.edu.cn

Prof. Ye Gu,  
Department of Pediatric Surgery, The Second Hospital of Jilin University, Nangan District, Changchun 130041, China.  
E-mail: 290089123@qq.com

Submitted: 22-Aug-2025  
Revised: 11-Nov-2025  
Accepted: 11-Nov-2025  
Published: 31-Dec-2025

auxiliary forceps to the laparoscope complicates the surgery. Some physicians create specialized devices for surgical procedures; however, these devices frequently experience limited acceptance in resource-constrained environments.<sup>[6-8]</sup> This associated steep learning curve also increases the risk of injury and recurrence during the early stages of a surgeon's experience. To reduce these limitations, we have refined and condensed the single-port laparoscopic inguinal hernia repair technique, drawing upon prior surgical research and extensive clinical experience. This technique necessitates only standard epidural puncture needles and is executed through a two-step puncture and ligation process. The objective of this study is to evaluate the clinical utility, feasibility, and safety of this approach.

## Materials and Methods

### Study design, setting, and participants

A retrospective analysis of the inguinal hernia was conducted from January 2019 to August 2024 at the Second Affiliated Hospital of Jilin University. Around 529 patients, aged 6 months to 16 years who were diagnosed with inguinal hernia through clinical, physical, and imaging examinations, were included. Postoperative recurrence, giant hernia, and incarcerated hernia were excluded. Relevant surgical data were collected and analyzed [Table 1]. The study protocol was approved by the Ethics and Safety Committee of our hospital.

### Statistical analysis used

The statistical data were analyzed by IBM Statistical Package for the Social Sciences Statistics 22, which was developed by International Business Machines Corp., Armonk, New York, USA. Categorical variables were described using counts and percentages. Continuous variables were expressed as median and standard deviation ( $x \pm S$ ).

### Surgical procedure

Under general anesthesia, the patient was placed in the supine position, and a 5 mm incision was made

at the umbilicus. A 5 mm port was inserted into the incision [Figure 1] and a 30-degree laparoscope was utilized to explore the closure of the vaginalis process [Figure 2] after achieving pneumoperitoneum. A common 22-gauge syringe needle was used to puncture the site superior to the internal inguinal ring. After puncturing, the needle was removed. The suture was folded in the middle and threaded through an epidural needle [Figure 3], which was then passed through the subcutaneous tissue and muscle layers and finally into the outer abdominal space. The peritoneum was perforated by circumventing the inner half of the inner ring opening close to the peritoneum, during which the vas deferens and spermatic vessels were protected. For patients with peritoneal adhesions, normal saline can be injected through an epidural needle to facilitate separation. Ligation line A was introduced, and the epidural needle was removed to form coil A [Figure 4]. The epidural needle was placed on the outer half of the inner ring opening at the same puncture point to penetrate the peritoneum and pass through coil A. After ligation line B was introduced [Figure 5], the epidural needle was removed, the ligation line A was tightened, and the other end of ligation line B was removed. Silk thread C was introduced using the same method. After assessing the integrity of the inner ring opening, the

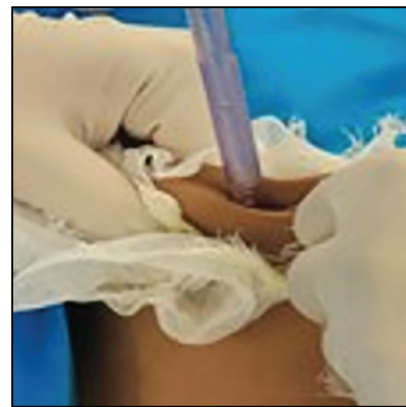

Figure 1: The trocar was inserted into the umbilical incision.

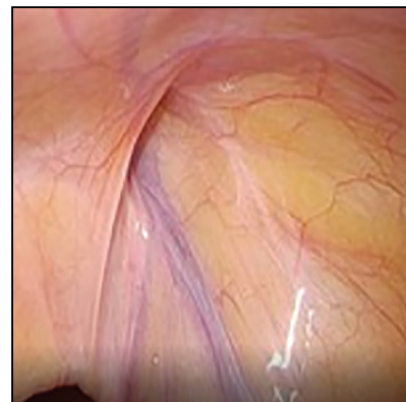

Figure 2: Exploring the closure of the processus vaginalis

**Table 1: Data for patients who underwent our laparoscopic hernial repair technique**

Total patient	529
Sex	
Male	448 (84.7%)
Female	81 (15.3%)
Age ( $x \pm S$ , year)	3.71 $\pm$ 2.69 (6 months to 16 years)
Side of the hernia	
Unilateral	249 (47.1%)
Bilateral	280 (52.9%)
CPPV	208 (39.3%)

CPPV = contralateral patent processus vaginalis

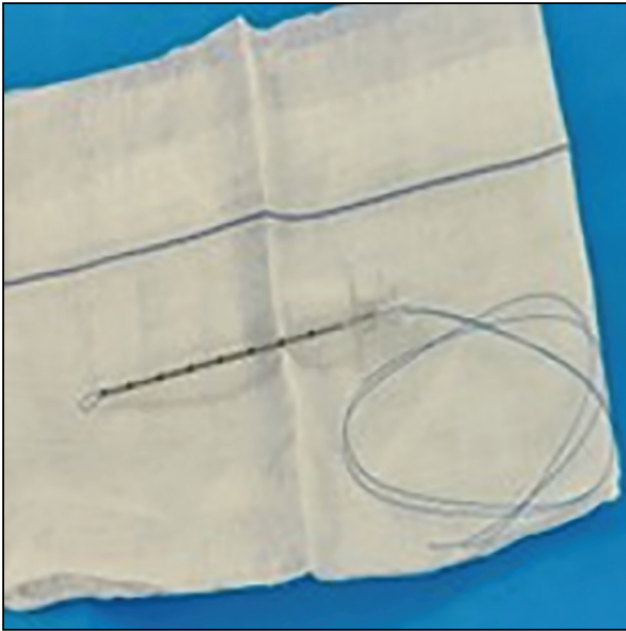

Figure 3: A 18-gauge epidural needle

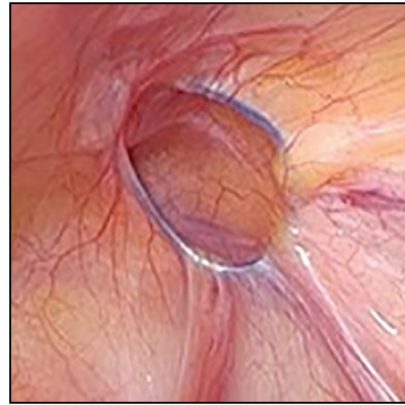


Figure 6: Condition of the internal ring orifice before ligation

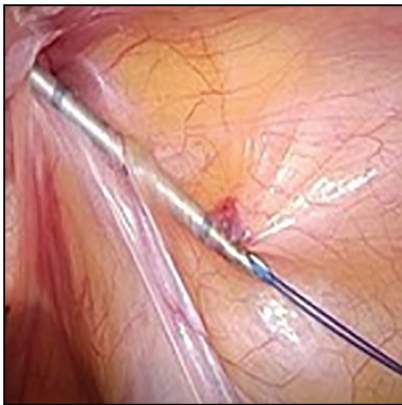

Figure 4: An epidural needle with a suture line is used to slowly move across the vas deferens along the inner ring

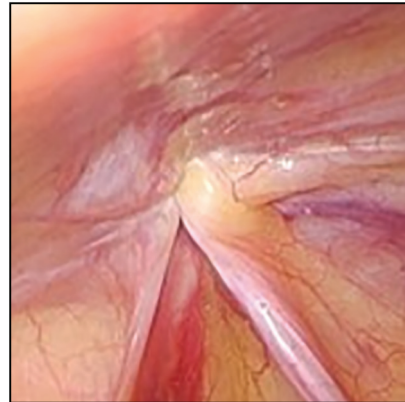


Figure 7: The sutures were tightened

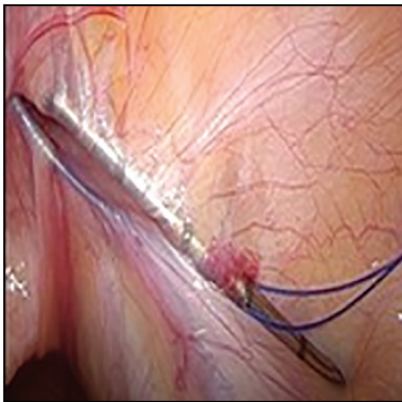


Figure 5: Introduction of ligation line B

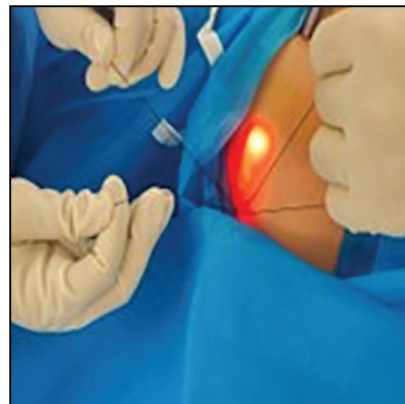


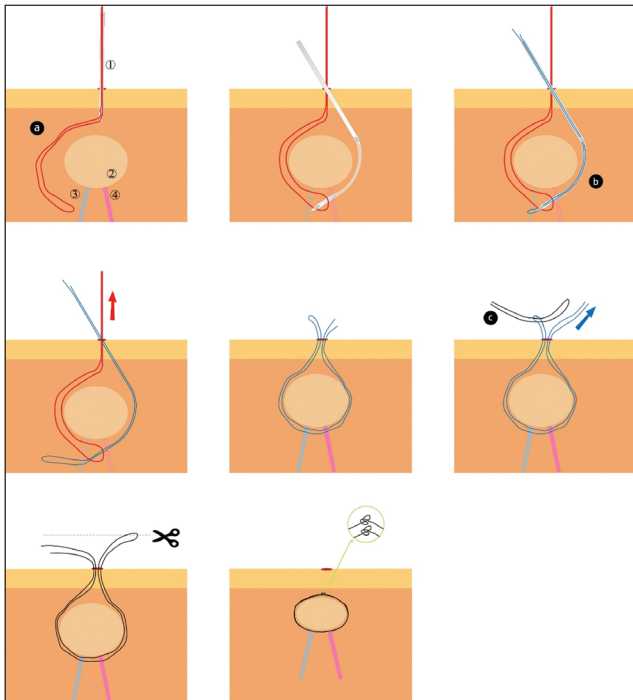
Figure 8: An external knot was tied

other section of the ligation line C was cut short, the inner ring opening was closed with double ligation [Figure 6], the sutures were tightened [Figure 7], and an external knot was tied [Figure 8]. After ensuring

that there was no bleeding, the instruments were examined, and the umbilical incision was closed with an intradermal suture. If similar conditions were identified on the opposite side, a similar procedure was executed, eliminating the necessity for sutures at the puncture site [Figure 9].

## Results

Of the 529 patients, 448 were male and 81 were female, with a mean age of  $3.71 \pm 2.69$  years. Of these, 280 patients (52.9%) underwent bilateral surgery, and 208



**Figure 9:** This is a schematic diagram of high ligation. ① A 18-gauge epidural needle ② internal ring ③ Spermatic cord vessel ④ Vas deferens

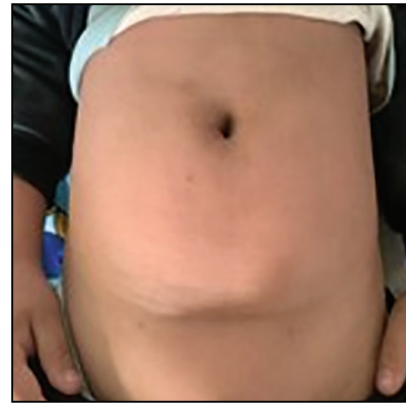
**Table 2: Perioperative clinical data**

Item	
Operating time (x ± S, min)	
Unilateral	13.42 ± 4.42
Bilateral	19.20 ± 2.49
Follow-up (x ± S,m)	14.12 ± 3.45
Hospital stay(x ± S, d)	2.16 ± 0.70
Converted to open surgery	0
Additional port	30 (5.7%)

**Table 3: Postoperative complications**

Item	
Abdominal adhesion	0
Incision infection	0
hematoma	0
Recurrence	1 (0.1%)
Testicular vascular injury	0
Vasectomy injury	0
Abdominal vascular injury	0

patients (39.3%) had a contralateral patent processus vaginalis. The mean operation time of unilateral hernia repair was  $13.42 \pm 4.42$  min, and the mean operation time of bilateral hernia repair was  $19.20 \pm 2.49$  min [Table 2]. Of all the patients, one had a recurrence that required surgery again; a new inguinal hernia had appeared in the same site. In addition, in 30 patients (5.7%), due to congenital adhesion or scarring at the inner ring opening, additional operating forceps were added to the umbilicus. In terms of postoperative complications, there were no surgical site infections, testicular atrophy, or abdominal



**Figure 10:** Postoperative wound healing

adhesion. The mean follow-up time was  $14.12 \pm 3.45$  months. During this period, the postoperative recovery was rapid, and no chronic pain was found [Table 3]. The family members were satisfied with the cosmetic degree of the surgery, and almost no surgical scars were observed [Figure 10].

## Discussion

Open surgical repair has long been regarded as the gold standard for treating pediatric inguinal hernias. However, the progression of minimally invasive techniques has led to laparoscopic surgery becoming an extensively studied alternative, providing specific benefits such as improved visualization for accurate hernia sac localization, secure high ligation of the internal ring, and decreased operative durations.<sup>[9–12]</sup>

Most reported traditional laparoscopic inguinal hernia surgeries use the three-port or two-port method,<sup>[13,14]</sup> and the single-port approach is rarely employed. Compared to the single-port surgery, the traditional multi-port method is more complex. Due to the limited abdominal space in children, forceps or a needle holder within the confined space may cause additional tissue trauma. In our procedures, we looked inside the abdominal cavity through an umbilical incision, percutaneously accessing the internal ring only via an epidural needle insertion through the skin. This avoids mutual instrument interference during laparoscopy and complex intracorporeal suturing and knot tying. This single-port technique reduces operative time compared to conventional multi-port methods. A recent review indicated that the laparoscopic operation time for unilateral hernia was approximately 20–30 min, and for bilateral hernia, it was approximately 30–35 min.<sup>[15]</sup> Unilateral hernia repairs using this method demonstrated an average duration of 13 min, while bilateral repairs required 19 min.

In the single-port laparoscopic surgery, the absence of auxiliary forceps renders the process of threading the

ligature around the inner ring problematic. To address this issue, several specialized devices have been proposed, including the diathermy probe, needle grasper, and the “two-hooked” core needle.<sup>[6,7,16]</sup> Many of these devices feature grasping mechanisms designed to replicate auxiliary forceps; however, their limited availability and the potential for vessel or vas deferens damage due to the small grasper during ligature manipulation may exacerbate the risk of uncontrollable bleeding or a significant hematoma resulting from vessel injury.<sup>[17,18]</sup> We chose to utilize the common and safe epidural needle, whose blunted tip helps avoid accidental opening of the peritoneum while passing along the preperitoneal space and damage to adjacent structures. We did not observe any major early postoperative complications, including hematoma.

Some studies have demonstrated that the recurrence rate for this type of external suture is low.<sup>[19,20]</sup> However, a study also suggested a relatively high recurrence rate for percutaneous internal ring closure,<sup>[21]</sup> indicating that postoperative recurrence may arise from interfering soft tissues between the inner ring and ligature site or ligature relaxation after tissue trauma.<sup>[22,23]</sup> To address these limitations, we have refined a method by utilizing a puncture path, trying to allow the suture to enter and exit at the same location and keep the knot close to the inner ring. This technique guarantees that the tightened tissue is the peritoneum while minimizing subcutaneous residual tissue within the ligature loop.

In addition, a single-wire ligation of the inner ring opening demonstrates potential limitations, including ring diameter expansion secondary to inadequate tension or effects of intra-abdominal pressure. A double-wire ligation of the inner ring was used to distribute the tensile load between the two wires, significantly reducing the risk of knot breakage and loosening. Thus, extraperitoneal double complete circuit ligation is an effective method for reinforcing the peritoneum. However, this technique necessitates going through two tunnels and taking two detours around the inner ring for high-position ligation, which could lengthen the operation’s duration and make it more challenging.<sup>[24]</sup> Therefore, we modified the technique by circling the inner ring entrance only once in a tunnel. This exhibits simplicity and efficiency, without necessitating additional procedural steps or causing extra tissue trauma.

To prevent recurrences, the material selected is critical.<sup>[23,25]</sup> When choosing sutures, non-absorbable silk sutures are recommended because absorbable sutures have a higher recurrence rate than non-absorbable sutures when used to ligate the inner ring.<sup>[26-28]</sup> Moreover, silk thread is regarded as the ideal ligation material owing to its remarkable flexibility, reliable knot security,

and superior tensile strength; likewise, it may induce foreign body inflammation and a stimulatory reaction in the tissue, leading to scar formation that enhances the closure of the inner ring.<sup>[29,30]</sup>

This study observed one recurrence necessitating reoperation in a premature neonate born at less than 30 weeks’ gestation; the repair was conducted in the same manner, and no recurrence was noted during the subsequent follow-up. We believe that the biggest reason was the congenital weakness of the peritoneum. Another patient developed a contralateral inguinal hernia during follow-up. Intraoperative exploration verified the integrity of the original ligation site, concluding that the new hernia resulted from congenital peritoneal deficiency. For these patients, we therefore advise using the epidural needle-mediated suture technique between the abdominal wall lateral to the hernia sac ligation site and the medial peritoneal fold. This approach addresses congenital peritoneal deficiency-related defects and demonstrates potential to reduce recurrence rates. Overall, the safety and effectiveness of the proposed technique have been shown in this study.

Using a simplified epidural needle technique, we report 529 consecutive pediatric cases that underwent micro-laparoscopic inguinal hernia repair over a 6-year study period. Among the cases studied, 30 (5.6%) patients with hernia had scar hyperplasia at the inner ring opening or greater omental adhesive. A paramedian umbilical port was used to introduce forceps after a thorough surgical risk assessment. The natural umbilical fold successfully covered up the umbilical scar from the laparoscope and forceps placement. At the same time, the epidural needle puncture sites remain practically imperceptible, thereby achieving superior cosmetic results.

However, this study also has some limitations. To fully assess the applicability of this technique, multi-center studies are required to confirm the results of this single-center study. Longer follow-up data are needed to more precisely ascertain long-term outcomes and the prevalence of postoperative complications, as the follow-up period is comparatively brief. Moreover, the surgical technique may need to be practiced multiple times to be utilized safely and effectively.

## Conclusion

We have used a single-hole laparoscopic technique that enables detailed observation through a laparoscope from a 5-mm incision. The surgical treatment was performed using a readily available epidural needle. This strategy achieves high technical success and safety with positive clinical outcomes, according to a retrospective analysis of 529 children with inguinal hernias treated surgically

over a 6-year period. This surgical technique offers a number of noteworthy benefits, such as quick recovery, a very low chance of recurrence, aesthetically pleasing outcomes, and inexpensive treatment. Therefore, in the clinical practice of treating children with inguinal hernia, the single-port approach should be widely promoted, particularly in resource-limited settings.

### Author contributions

We certify that we have participated sufficiently in the intellectual content, conception, and design of this work or the analysis and interpretation of the data (when applicable), as well as the writing of the manuscript, to take public responsibility for it and have agreed to have our name listed as a contributor.

### Ethical policy and Institutional Review board statement

This study was approved by the Ethics Committee of the Second Hospital of Jilin University. This research protocol has been exempted from the informed consent form procedure that was reviewed by the Ethics Committee of the Second Hospital of Jilin University and certifies that the study was performed in accordance with the ethical standards as laid down in the 1964 Declaration of Helsinki. IRB board name: the Second Hospital of Jilin University. Approval number: IRB-2025-049. The date of approval: January 26, 2025.

### Declaration of patient consent

This research protocol has been exempted from the informed consent form procedure that was reviewed by the Ethics Committee of the Second Hospital of Jilin University, so I am unable to provide the declaration of patient consent.

### Data availability statement

The data for this retrospective study were all sourced from the database of the Second Hospital of Jilin University, fully safeguarding patient privacy, and all raw data are available.

### Financial support and sponsorship

Nil.

### Conflicts of interest

Nil.

### Acknowledgments

Nil.

## References

- Kantor N, Travis N, Wayne C, Nasr A. Laparoscopic versus open inguinal hernia repair in children: Which is the true gold-standard? A systematic review and meta-analysis. *Pediatr Surg Int* 2019;35:1013-26.
- Esposito C, Escolino M, Turrà F, Roberti A, Cerulo M, Farina A, *et al.* Current concepts in the management of inguinal hernia and hydrocele in pediatric patients in laparoscopic era. *Semin Pediatr Surg* 2016;25:232-40.
- Jessula S, Davies DA. Evidence supporting laparoscopic hernia repair in children. *Curr Opin Pediatr* 2018;30:405-10.
- Kozlov Y, Novozhilov V. Technology of single-incision laparoscopic surgery in treatment of inguinal hernia in small babies. *J Laparoendosc Adv Surg Tech Part A* 2015;25:526-30.
- Helal AA. Laparoscopic single instrument closure of inguinal hernia in female children: A novel technique. *J Pediatr Surg* 2015;50:1613-6.
- Chen P, Li S, Yu L, Jin S, Su J, Yang Z, *et al.* Single-port laparoscopic percutaneous extraperitoneal internal ring closure for paediatric inguinal hernia using a needle grasper. *Pediatr Surg Int* 2022;38:1421-6.
- Yonggang H, Changfu Q, Ping W, Fangjie Z, Hao W, Zicheng G, *et al.* Single-port laparoscopic percutaneous extraperitoneal closure of inguinal hernia using "two-hooked" core needle apparatus in children. *Hernia* 2019;23:1267-73.
- Zeng D, Pu C, Guo C, Kong X. Outcomes from a new modified single needle laparoscopic percutaneous extraperitoneal closure and cut off for pediatric inguinal hernia. *Sci Rep* 2024;14:12029.
- Davies DA, Rideout DA, Clarke SA. The International Pediatric Endosurgery Group evidence-based guideline on minimal access approaches to the operative management of inguinal hernia in children. *J Laparoendosc Adv Surg Techn Part A* 2020;30:221-7.
- Chong AJ, Fevrier HB, Herrinton LJ. Long-term follow-up of pediatric open and laparoscopic inguinal hernia repair. *J Pediatr Surg* 2019;54:2138-44.
- Zhang Y, Chao M, Zhang X, Wang Z, Fan D, Zhang K, *et al.* Does the laparoscopic treatment of paediatric hydroceles represent a better alternative to the traditional open repair technique? A retrospective study of 1332 surgeries performed at two centres in China. *Hernia* 2018;22:661-9.
- Shalaby R, Abd Alrazek M, Elsaied A, Helal A, Mahfouz M, Ismail M, *et al.* Fifteen years experience with laparoscopic inguinal hernia repair in infants and children. *J Laparoendosc Adv Surg Tech Part A* 2018;28:101-5.
- Shalaby R, Ismail M, Dorgham A, Hefny K, Elsaied G, Gabr K, *et al.* Laparoscopic hernia repair in infancy and childhood: Evaluation of 2 different techniques. *J Pediatr Surg* 2010;45:2210-6.
- Son TN, Bao HV, Van NTH, Hiep PD, Mai DV, Quyet TV. Modifications of surgical techniques in laparoscopic percutaneous extraperitoneal closure of inguinal ring for childhood inguinal hernia to achieve zero recurrence and zero subcutaneous stitch granuloma. *Pediatr Surg Int* 2024;40:187.
- Luo H, Xu J, Chen J, Ni Z. Clinical efficacy of laparoscopic treatment of pediatric inguinal hernia: A meta-analysis. *Am J Transl Res* 2024;16:5155-67.
- Shalaby R, Negm M, El-Sawaf M, Elsaied A, Shehata S, Hamed A, *et al.* Needlescopic disconnection and peritoneal closure for pediatric inguinal hernia repair: A novel technique. *Surg Laparosc Endosc Percutan Tech* 2022;32:272-8.
- Korkmaz M, Güvenç BH. Comparison of single-port percutaneous extraperitoneal repair and three-port mini-laparoscopic repair for pediatric inguinal hernia. *J Laparoendosc Adv Surg Tech* 2018;28:337-42.
- Thomas DT, Göcmen KB, Tulgar S, Boga I. Percutaneous internal ring suturing is a safe and effective method for the minimal invasive treatment of pediatric inguinal hernia: Experience with 250 cases. *J Pediatr Surg* 2016;51:1330-5.
- Thomas DT, Sag S, Kalyoncu Aycenk A, Tulgar S. Percutaneous internal ring suturing for inguinal hernia repair in children: Retrospective cohort of 714 patients with minimum 3-year follow-up. *Medicina (Kaunas, Lithuania)* 2024;60:1137.

20. Svetanoff WJ, Fraser JA, Briggs KB, Staszak JK, Dekonenko C, Rentea RM, *et al.* A single institution experience with laparoscopic hernia repair in 791 children. *J Pediatr Surg* 2021;56:1185-9.
21. Kilda A, Berzanskis M, Lukosiute-Urboniene A, Malcius D, Barauskas V. High recurrence rate of children's inguinal hernia after percutaneous internal ring suturing: A single-center study. *Hernia* 2021;25:797-801.
22. Chang Y-T, Wang J-Y, Lee J-Y, Chiou C-S. A simple single-port laparoscopic-assisted technique for completely enclosing inguinal hernia in children. *Am J Surg* 2009;198:e13-6.
23. Ozgediz D, Roayaie K, Lee H, Nobuhara KK, Farmer DL, Bratton B, *et al.* Subcutaneous endoscopically assisted ligation (SEAL) of the internal ring for repair of inguinal hernias in children: Report of a new technique and early results. *Surg Endosc* 2007;21:1327-31.
24. Duan S, Zhang P, Lin X, Zheng L. Laparoscopic percutaneous extraperitoneal closure with peritoneum reinforcement repair for pediatric inguinal hernia: A single-center experience with over 2,000 patients. *Transl Pediatr* 2021;10:1317-23.
25. Takehara H, Yakabe S, Kameoka K. Laparoscopic percutaneous extraperitoneal closure for inguinal hernia in children: Clinical outcome of 972 repairs done in 3 pediatric surgical institutions. *J Pediatr Surg* 2006;41:1999-2003.
26. Chen Y, Wang F, Zhong H, Zhao J, Li Y, Shi Z. A systematic review and meta-analysis concerning single-site laparoscopic percutaneous extraperitoneal closure for pediatric inguinal hernia and hydrocele. *Surg Endosc* 2017;31:4888-901.
27. Wang C, Wang Y, Zhong M, Li R, Shen Z. Logistic analysis of the recurrence of laparoscopic percutaneous extraperitoneal repair of pediatric inguinal hernia: A report of 486 cases. *Asian J Surg* 2024;47:134-9.
28. Son TN, Bao HV. Long-term absorbable versus non-absorbable suture in laparoscopic percutaneous extraperitoneal closure of internal ring for inguinal hernia in children. *J Pediatr Surg* 2021;56:1127-31.
29. Kelly KB, Krpata DM, Blatnik JA, Ponsky TA. Suture choice matters in rabbit model of laparoscopic, preperitoneal, inguinal hernia repair. *J Laparoendosc Adv Surg Tech Part A* 2014;24:428-31.
30. Elbatarny AM, Khairallah MG, Elsayed MM, Hashish AA. Laparoscopic repair of pediatric inguinal hernia: Disconnection of the hernial sac versus disconnection and peritoneal closure. *J Laparoendosc Adv Surg Tech Part A* 2020;30:927-34.