

Access this article online

Quick Response Code:



Website:

www.herniasurgeryjournal.org

DOI:

10.4103/ijawhs.ijawhs\_85\_24

# Strangulated bowel obstruction secondary to a pericecal hernia: A case report

Juba Mansouri, Sif el I. Meharzi, Anisse Tidjane, Mohamed H. Larbi, Nacim Ikhlef, Anissa Ilham Ourabah, Benali Tabeti

## Abstract

Internal hernias are a rare cause of acute intestinal obstruction, accounting for approximately 5.8% of all cases. Pericecal hernias, the second most common type of internal hernia, remain challenging to diagnose preoperatively, owing to the lack of specific clinical signs. Abdominal computed tomography is an essential examination, as it allows the diagnosis of acute intestinal obstruction, especially its etiology and signs of severity, such as intestinal ischemia. We report a case of a 35-year-old man who presented with small bowel obstruction with suspicion of pericecal hernia. An emergency laparotomy confirmed the diagnosis of a retrocecal hernia with the identification of four loops of ischemia requiring resection. Our case highlights the importance of considering this diagnosis in cases of acute abdominal pain, especially in acute intestinal obstruction, and emphasizes the crucial role of surgery in confirming the diagnosis, preventing complications, and treating the obstruction.

## Keywords:

Internal hernia, pericecal hernia, retrocecal hernia, small bowel obstruction

## Introduction

Internal hernias are a rare but significant cause of small bowel obstruction, accounting for approximately 5.8% of all cases.<sup>[1]</sup>

Pericecal hernias, the second most common type, present diagnostic challenges owing to their rare occurrence and non-specific symptoms.<sup>[1]</sup>

Computed tomography (CT) is a key tool for the diagnosis of intestinal obstruction and acute abdominal conditions. It has become an essential examination in case of suspicion of internal hernia.<sup>[2]</sup> Emergency surgery is often the only way to confirm the diagnosis and treat the condition.<sup>[2,3]</sup>

We present the case of a 35-year-old male who presented with small bowel obstruction secondary to a pericecal hernia.

## Case Presentation

A 35-year-old man, without a specific medical or surgical history, a chronic smoker, and a body mass index of 19.3 kg/m<sup>2</sup>, presented to the emergency room with abdominal pain lasting for 48 h and associated with nausea and three episodes of vomiting.

On clinical examination, the patient was in good general condition, with a blood pressure of 110/60 mmHg, a heart rate of 82 beats/min, and a temperature of 37.1°C.

Abdominal examination revealed slight abdominal distension with tenderness on palpation of the right iliac fossa and free hernial orifices.

This is an open access journal, and articles are distributed under the terms of the Creative Commons Attribution-NonCommercial-ShareAlike 4.0 License, which allows others to remix, tweak, and build upon the work non-commercially, as long as appropriate credit is given and the new creations are licensed under the identical terms.

For reprints contact: WKHLRPMedknow\_reprints@wolterskluwer.com

**How to cite this article:** Mansouri J, Meharzi Sel, Tidjane A, Larbi MH, Ikhlef N, Ourabah AI, *et al.* Strangulated bowel obstruction secondary to a pericecal hernia: A case report. *Int J Abdom Wall Hernia Surg* 2025;8:135-8.

Surgeon, Chief  
of Department,  
Établissement Hospitalo-  
universitaire 1er novembre  
1954, Oran, Algeria

### Address for correspondence:

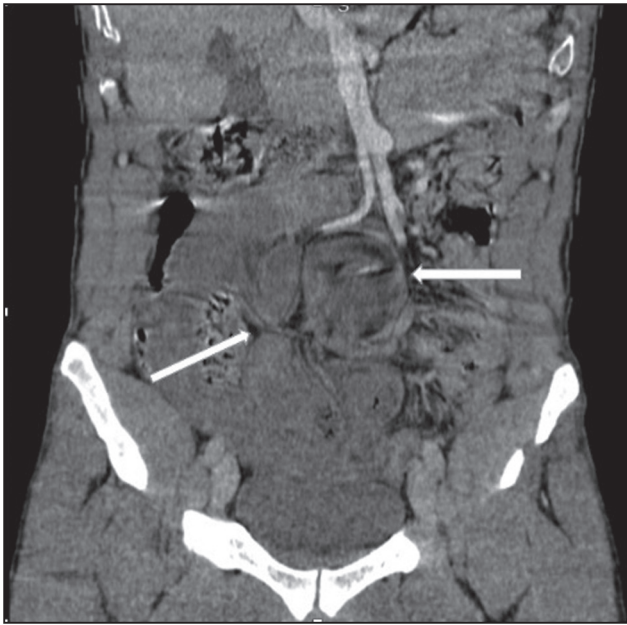Dr. Juba Mansouri,  
Surgeon, Établissement  
Hospitalo-universitaire  
1er novembre 1954,  
31000 Oran, Algeria.  
E-mail: jubamansouri91@  
gmail.com

Submitted: 08-Nov-2024

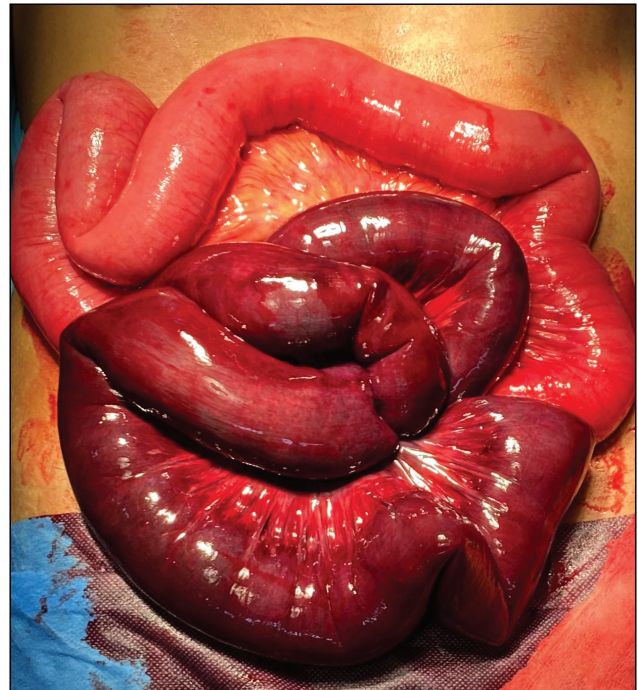Revised: 10-Jan-2025

Accepted: 21-Jan-2025

Published: 23-Jun-2025



**Figure 1:** Contrast-enhanced coronal computed tomography scan image that shows multiple bowel loops and a bird's beak appearance in the paracecal region



**Figure 2:** Intraoperative findings

Blood tests revealed an increase in white blood cells of  $12,500/\text{mm}^3$ , otherwise the rest was unremarkable.

A standard X-ray revealed air-fluid levels in the bowel loops, with the horizontal dimension of the levels being significantly greater than their vertical dimension. This finding is suggestive of mechanical small bowel obstruction.

An abdominopelvic CT scan was performed and showed a small intestinal obstruction, with multiple bowel loops and a bird's beak appearance in the paracecal region, with suspicion of ischemia of the loop due to reduced contrast [Figure 1].

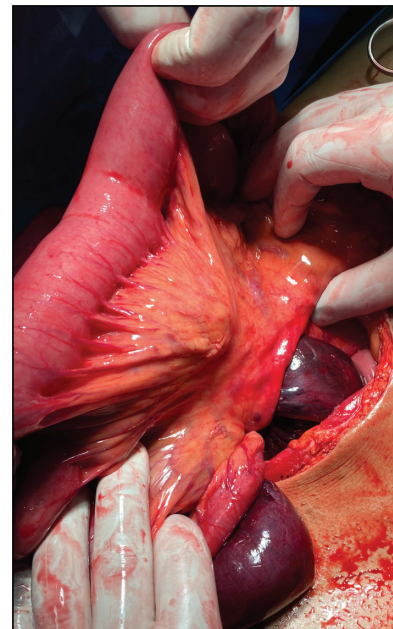
At the end of these examinations, we concluded that there was an acute mechanical intestinal obstruction with a probable internal hernia.

Given the clinical presentation and radiological findings, we proceeded directly to an emergency exploratory laparotomy that confirmed the presence of a pericecal internal hernia in its retrocecal form, with four bowel loops strangulated and ischemic [Figure 2].

The herniated bowels were reduced, followed by ileocecal resection removing 60 cm of ileal loop with manual ileocolic anastomosis and closure of the mesenteric defect [Figure 3].

The total operative time was 125 min.

The postoperative course was uneventful, with a return of bowel function on day 2 and oral intake well tolerated. The patient was discharged on postoperative day 4.



**Figure 3:** Intraoperative findings showing four ileal loops incarcerated in the retrocecal fossa

## Discussion

Internal hernias are a rare cause of small bowel obstruction and represent approximately 5.8% of cases.<sup>[1]</sup>

Internal hernias are defined as a protrusion of a viscus through a normal or abnormal peritoneal or mesenteric aperture, within the abdominal cavity. These hernias most often contain the small intestine.<sup>[1,4]</sup>

Meyers classified internal hernias based on their location, identifying several types with varying frequencies.<sup>[5]</sup> The most common is the paraduodenal hernia (53%), followed by pericecal (13%), hernias through the foramen of Winslow (8%), trans mesenteric and trans mesocolic (8%), inter-sigmoid (6%), and retro anastomotic (5%).

Paraduodenal hernias often present with left upper quadrant pain and bowel obstruction, with CT showing clustered bowel loops near the ligament of Treitz. In contrast, hernias through the foramen of Winslow can result in gastric outlet obstruction, with CT revealing a distended stomach and herniated bowel loops in the lesser sac.

Pericecal hernias are the second most common type of internal hernias. The pericecal fossa is located behind the cecum and the ascending colon, limited by the parieto-cecal fold externally and the mesenterico-cecal fold internally.<sup>[4]</sup>

There are four subtypes: ileocolic, retrocecal, ileocecal, and paracecal.<sup>[4]</sup> Most pericecal hernias involve an ileal segment protruding into the pericecal fossa and extending toward the right paracolic gutter.<sup>[5]</sup> In our case, the hernia was retrocecal.

Pericecal hernias are challenging to diagnose preoperatively due to their rare occurrence and non-specific symptoms.<sup>[6,7]</sup> Patients often experience intermittent pain in the right iliac fossa, which may progress to acute small bowel obstruction, or sometimes a palpable mass.<sup>[7,8]</sup> The symptoms are similar to those of a small bowel obstruction and include abdominal pain, nausea, vomiting, and constipation.<sup>[2]</sup>

The CT scan allows for the diagnosis of small bowel obstruction, especially when an internal hernia is suspected.<sup>[2]</sup> It surpasses conventional radiology by pinpointing the obstruction site, identifying the underlying cause, and detecting signs of severity, such as ischemia and perforation.<sup>[9]</sup>

In the case of a pericecal hernia, CT findings typically show fluid-filled small bowel loops located on the lateral side of the cecum and behind the ascending colon, with a bird's beak transition zone at the peritoneal defect.<sup>[8]</sup>

The treatment of strangulated internal hernias requires emergency surgery.<sup>[2]</sup> It consists, firstly, of the reduction in the strangulated loop and, secondarily, closing or opening of the hernial orifice to prevent a recurrence.<sup>[2,3,6]</sup>

Laparoscopic surgery has been increasingly popular for treating small intestinal obstructions and plays an increasingly prominent role in the diagnosis and

management of internal hernias. It allows direct visualization of the hernia defect and enables the education of herniated bowel and defect closure.<sup>[10]</sup>

However, in our case, we preferred an exploratory laparotomy. The decision was based on the significant dilation of the upstream bowel loops, which limited the use of pneumoperitoneum, and the high suspicion of ischemia. Under these circumstances, performing resection and anastomosis was deemed safer through open surgery.<sup>[2,3]</sup>

## Conclusion

Pericecal hernia is an uncommon yet plausible cause of acute intestinal obstruction. Preoperative CT can help direct our diagnostic approach toward this specific condition. Emergency surgical intervention is paramount for definitive diagnosis and management of the obstruction. It should be noted that laparoscopic surgery is gaining prominence in the treatment of intestinal occlusions.

## Author contributions

The manuscript has been read and approved by all authors. Each author believes that the manuscript represents honest work and that the requirements for authorship have been met. All authors have approved the final version of this manuscript.

## Ethical policy and institutional review board statement

Not applicable.

## Declaration of patient consent

The authors certify that they have obtained all appropriate patient consent forms. In the form, the patient(s) has/have given his/her/their consent for his/her/their images and other clinical information to be reported in the journal. The patients understand that their names and initials will not be published, and due efforts will be made to conceal their identity, but anonymity cannot be guaranteed.

## Data availability statement

The datasets generated during and/or analyzed during the current study are available from the corresponding author on reasonable request.

## Financial support and sponsorship

Nil.

## Conflicts of interest

There are no conflicts of interest.

## Acknowledgments

Not applicable.

## References

1. Martin LC, Merkle EM, Thompson WM. Review of internal hernias: Radiographic and clinical findings. *AJR Am J Roentgenol* 2006;186:703-17.
2. Yokota T, Otani K, Yoshida J, Mochidome N, Miyatake E, Nakahara C, *et al.* Paracecal hernia due to membranous adhesion of the omentum to the right paracolic gutter. *Surg Case Rep* 2019;5:183.
3. Ong J, Tan W, Lee KS, Yeong KY, Seow CS. Surgical management of pericaecal hernia in a virgin abdomen. *Cureus* 2022;16:e56192.
4. Smith GH, Skipworth RJ, Duff MD, Anderson DN. Red herring: A rare cause of small bowel obstruction. *Surgeon* 2006;4:107-10.
5. Meyer A, Nowotny K, Poeschl M. Internal hernias of the ileo-cecal region. *Erqeb Chir Orthop* 1963;44:176-204.
6. Ito S, Takeda R, Kokubo R, Sakai Y, Matsuzawa H, Sugimoto K, *et al.* Retrocecal hernia preoperatively diagnosed by computed tomography: A case report. *Int J Surg Case Rep* 2017;37:186-8.
7. Ogami T, Honjo H, Kusanagi H. Pericecal hernia manifesting as a small bowel obstruction successfully treated with laparoscopic surgery. *J Surg Case Rep* 2016;2016:rjw020.
8. Choh NA, Rasheed M, Jehangir M. The computed tomography diagnosis of paracecal hernia. *Hernia* 2010;14:527-9.
9. Lanzetta MM, Masserelli A, Addeo G, Cozzi D, Maggioletti N, Danti G, *et al.* Internal hernias: A difficult diagnostic challenge. Review of CT signs and clinical findings. *Acta Biomed.* 2019;90:20-37.
10. Son TQ, Hoc TH, Tung TT, Long VD, Dat NT, Dinh NQ, *et al.* Laparoscopic surgery for intestinal obstruction caused by an internal paracecal hernia. *Case Rep Gastroenterol* 2022;16:480-7.