

Access this article online

Quick Response Code:



Website:

www.herniasurgeryjournal.org

DOI:

10.4103/ijawhs.ijawhs_83_24

Treatment with negative pressure and biological mesh reconstruction of full-thickness abdominal wall necrosis due to a strangulated incisional hernia: A Case report

Elisabetta Iacobelli¹, Enrico Calisesi², Vinicio Rizza², Simone Cicconi², Renato Pietroletti¹

Abstract

Incisional hernia (IH) is not rare and is prone to a number of different complications. We present herein a case of a huge IH originating from a Pfannenstiel incision, complicated by bowel strangulation with gangrene and perforation and subsequent abdominal wall necrosis. The clinical presentation was delayed until a frank peritonism developed due to intestinal gangrene, accompanied by a large, full-thickness necrosis of the abdominal wall. The patient presented septic shock and was managed by extensive debridement, peritoneal toilet and drainage, intestinal resection, and ileostomy. The open abdomen treatment was established and subsequent intra-abdominal negative pressure therapy. After the resolution of sepsis and granulating tissue formation, stoma closure and implant of a biological mesh completed the treatment, achieving full healing of the abdominal wall. The open abdomen, coupled with intra-abdominal negative pressure therapy, is a well-established method for the management of abdominal wall defects due to congenital disorders, abdominal wall tumors, necrotizing infections, previous abdominal surgeries, trauma, and trauma-associated infections. Complications in large IH in obese patients may have a misleading clinical presentation causing delays in treatment and resulting in challenging situations. However, accurate treatment like that employed in this case warrants good results reducing hospital stays and costs.

Keywords:

Abdominal wall necrosis, incisional hernia, intestinal perforation, negative pressure wound therapy

Introduction

Incisional hernia^[1] (IH) refers to an abdominal hernia at the site of a surgical incision or abdominal wall injury. IH occurs in up to 20% of cases of abdominal surgeries, with higher frequency in the lower quadrants but the site of a Pfannenstiel bears the lowest incidence rate.^[2]

The mechanism of development of IH is multifactorial, including risk

factors such as surgical technique or suture materials, incision site, timing or urgency of the procedure, systemic, chronic diseases (diabetes, obesity, etc.), smoking, malnutrition, steroids, and immunosuppressants.^[1]

Progressive enlargement over a variable time span is usual, and bowel complications can occur resulting in incarceration, obstruction, or gangrene.^[1]

¹Surgical Coloproctology Unit,

²General Surgery Unit, Hospital Val Vibrata, Sant'Omero, Teramo, Italy

Address for correspondence:

Prof. Renato Pietroletti, Surgical Coloproctology Unit, Hospital Val Vibrata, Department of Applied Clinical and Biotechnological Sciences, University of L'Aquila, L'Aquila 67100, Italy.
E-mail: renato.pietroletti@univaq.it

Submitted: 03-Nov-2024

Revised: 15-Jan-2025

Accepted: 21-Jan-2025

Published: 23-Jun-2025

This is an open access journal, and articles are distributed under the terms of the Creative Commons Attribution-NonCommercial-ShareAlike 4.0 License, which allows others to remix, tweak, and build upon the work non-commercially, as long as appropriate credit is given and the new creations are licensed under the identical terms.

For reprints contact: WKHLRPMedknow_reprints@wolterskluwer.com

How to cite this article: Iacobelli E, Calisesi E, Rizza V, Cicconi S, Pietroletti R. Treatment with negative pressure and biological mesh reconstruction of full-thickness abdominal wall necrosis due to a strangulated incisional hernia: A case report. Int J Abdom Wall Hernia Surg 2025;8:139-43.

Perforation of a gangrenated loop of the intestine is life-threatening and requires emergency surgery to treat peritonitis and to resect the perforated/ischemic bowel.^[3]

We herein report a rare case of a patient who developed abdominal wall necrotizing fasciitis after small bowel perforation in a strangulated IH. After emergency surgery, with bowel resection, abdominal wall necrosectomy, ileostomy, and laparostomy, the application of intra-abdominal, negative pressure wound therapy (NPWT) allowed successful abdominal wall reconstruction.

Case Report

A 62-year-old female with a past medical history of diabetes and severe obesity (body mass index = 47.7) presented at the Emergency Unit of the Val Vibrata Hospital, complaining of severe abdominal pain at the lower quadrants, lasting for three days accompanied by nausea, vomiting, and fever (>39°C).

At physical examination, the abdomen was extremely distended and painful. A huge IH was visible in the hypogastrium starting from a Pfannenstiel scar and expanding upward. Peritonism was appreciated with

Blumberg in the lower quadrants and a large necrotic area visible on the skin [Figure 1A].

Blood tests showed leucocytosis (white blood cells >28 × 10³), hyperglycemia (>400 mg/dL), hypercreatininemia, hypoxemia, and metabolic acidosis due to sepsis.

A computed tomography scan of the abdomen [Figure 1B] showed a large hypogastric IH containing dilated, and edematous small bowel loops showing perivisceral hemorrhage and tiny gas bubbles suggestive of necrosis and perforation.

The patient required emergency surgery, and large spectrum multiple, i.v. antibiotic therapy was started with metronidazole, cephtriaxone, and levofloxacin.

At laparotomy, the IH was opened, and about 50 cm of gangrenated ileum, close to the ileocecal valve, was detected and resected, fashioning a terminal ileostomy in the right iliac fossa in a very lateral position to avoid wound contamination. This was facilitated by the large abdomen of the patient. Washing of the peritoneal cavity was performed together with the placement of drains. Removal of about 240 cm² of necrotic abdominal wall, including muscle, fascia, and skin, was necessary [Figure 2A]; thus, laparostomy was indicated [Figure 2B].

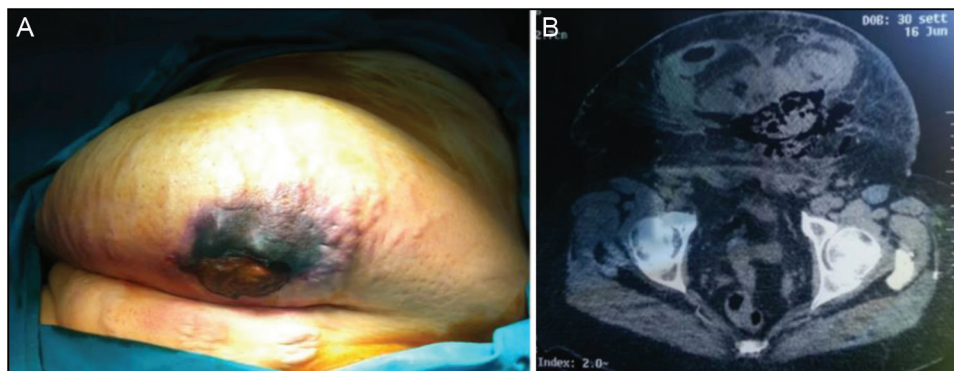


Figure 1: A. A huge incisional hernia (IH) with a necrotic skin area. B. computed tomography of the abdomen showing the IH almost entirely occupied by the small bowel. The intestine is dilated and edematous. Gas bubbles are visible

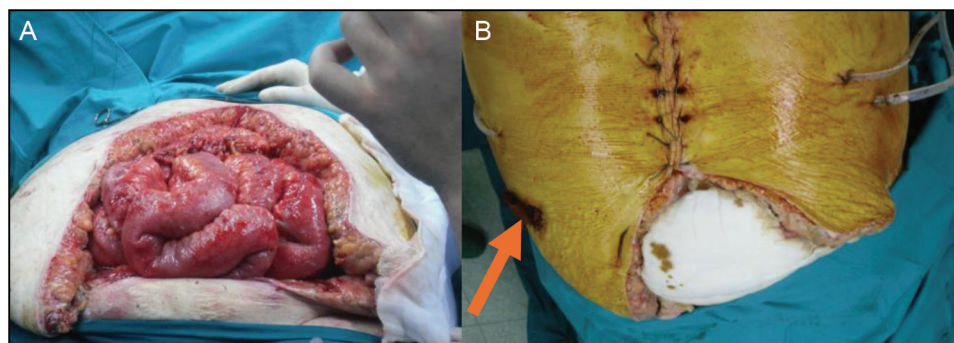


Figure 2: A. Abdominal wall defect after necrotic removal of necrotic tissue. B. Laparostomy and terminal ileostomy placed in a very lateral position (arrow)

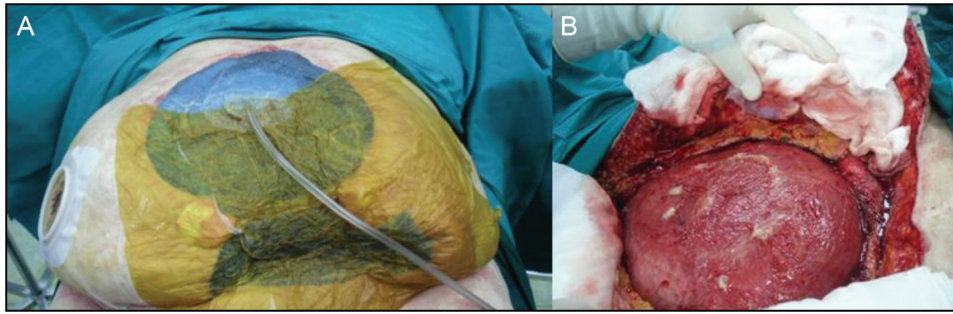


Figure 3: A. Intra-abdominal negative pressure wound therapy application. Note the stoma site is far away from the wound. B. Satisfactory formation of granulating tissue

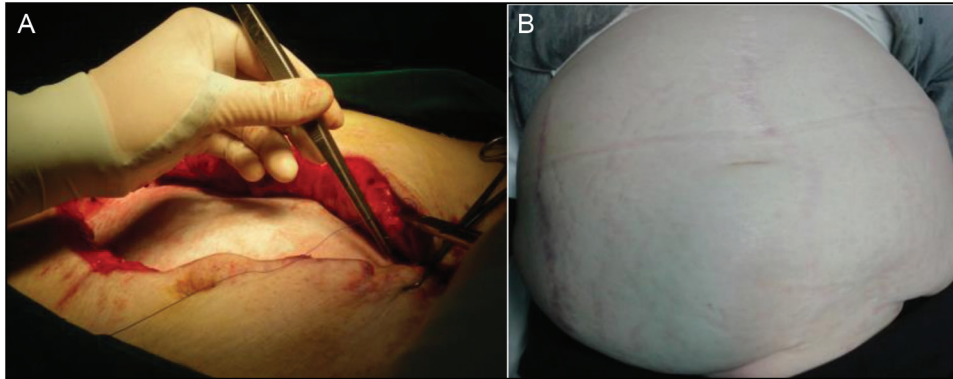


Figure 4: A. Biological mesh repair. B. Cosmetic result after two years

The patient was admitted to the intensive care and intubated under deep sedation. The ileostomy was managed with a two-piece system and an open-bottom stoma bag. The surgical site was debrided every 48 h in the operating room for one week. The wound was covered with gauze, soaked with saline to protect the bowel, and covered with antimicrobial incision drapes. Neither further bowel resection nor drainage of septic collections was required, and then, intra-abdominal NPWT was established [Figure 3A]. Wound dressing and canister were changed every 48–72 h, depending on the amount of exudate collection, leading to the progressive formation of granulating tissue.

In about two weeks, the granulating tissue was satisfactory [Figure 3B], and the patient was extubated, discharged from intensive care, and admitted to the surgical ward fully compensated for metabolic failures. NPWT was continued for a few days at low pressure and discontinued due to the very minimal amount of exudate.

Conventional dressing of the residual wound was performed using alginate and/or hydrocolloids dressing, changed as required with the further reduction of the abdominal wall defect. Methods for abdominal wall approximation have not been used, since the final size of the abdominal wall defect was not too large.

On postoperative day 51 from the emergency surgery, the residual abdominal defect was repaired using a biological mesh implant [Figure 4A]. The prosthesis was sutured to

the remnant of fascia on both sides, and then, the skin was mobilized with a thick amount of subcutaneous tissue and sutured over the prosthesis in a double layer with interrupted stitches. Two subcutaneous drains were left for 72 h.

The postoperative period was uneventful, and the patient was discharged home on the 60th postoperative day, in good general condition. After four months, the patient was evaluated for ileostomy closure. On physical examination, no recurrence of IH was detectable; the stoma appeared normal with satisfactory daily output. Thus, the ileostomy was closed using a manual side-to-side ileocecal anastomosis.

After 24 months of follow-up, the patient was in good health with no evidence of recurrent IH [Figure 4B].

Discussion

Complications of IH, including adhesions, intestinal obstruction, and bowel perforation, are well documented. Following the Pfannenstiel incision, IH shows a lower incidence than the midline incision^[2], and the catastrophic presentation that we reported in this case can be considered exceptional. The delay in the patient's presentation was probably related to the volume of the IH. Multiple adhesions blocked the gangrenated and perforated bowel, limiting the peritonitis at the beginning; subsequently, the abdominal wall was involved by enzymatic and septic damage causing necrosis of muscle and fascia.

Bowel perforation and emergency surgery may be both causes of complications, including sepsis, wound dehiscence, and IH. Abdominal wall gangrene with necrotizing fasciitis can be considered a very rare complication. A greater risk of wound and abdominal wall complications has been observed in emergency surgery compared to elective procedures.^[4] Our patient was treated in a very acute setting, showing features of septic shock due to strangulated and necrotic bowel into a large IH, and complicated by abdominal wall gangrene, causing necrotizing fasciitis and 240 cm² of muscle and skin gangrene. Ileostomy was necessary, with need of special care to avoid fecal contamination and infection of the wound. The large size of the abdomen and the initial technique of the open abdomen helped to keep the stoma far from the wound.

Necrosis of the abdominal wall is observed mainly in abdominal trauma such as multiple gunshot wounds, blast injuries, and extensive blunt trauma.^[5]

In such cases, the correct strategy includes damage control surgery (resection of gangrenated bowel, removal of necrotic abdominal wall, and stoma), peritoneal washing, multiple drainage, and open abdomen to avoid abdominal compartment syndrome. Subsequently, further procedures of washing and debridement ensure control of the sepsis, not to mention the need for multiple, wide-spectrum antibiotic therapy.

After the emergency surgery, the open abdomen/laparostomy needs special care; second-look procedures in OR, further debridement, and peritoneal washing achieve a clean field in one or two weeks. At this time, intra-abdominal NPWT improves granulating tissue formation. This allows a good management of the wound leading to complete recovery without lethal consequences, in spite of the severe clinical picture presented by patients in such conditions.^[6]

The adoption of intra-abdominal NPWT followed by mesh abdominal wall reconstruction significantly reduces rates of wound complication and skin dehiscence when compared with conventional dressings.^[7]

In such catastrophic clinical pictures, abdominal wall reconstruction is challenging, and different techniques have been adopted to improve results and reduce the costs of long hospital stays and need for repeated surgical procedures. Initially, the temporary abdominal closure method, NPWT, and Bogota bags can be employed with the aim of treating peritoneal infection and avoiding abdominal compartment syndrome. In the second instance, with the aim of reducing the gap of the abdominal fascia, other methods may be used for abdominal wall approximation, such as continuous fascial traction, Wittmann patches,

AbClo[®], NPWT, and final repair, usually with mesh. In our case, a good approximation of the abdominal wall was achieved just with the adoption of NPWT; thus, none of the mentioned support was needed.

In case of gangrenated or injured bowel, resection is mandatory, and stoma is not rarely needed as in the case observed by us. Stoma positioning and postoperative stoma care are crucial to avoid contamination of the wound. A very lateral position of the stoma with respect to the midline was possible in our case due to the large size of the abdomen. The adoption of the two-piece system for the ileostomy, with an open bottom to empty the bag, minimizes the risk of fecal contamination.

This was of utmost importance also when a mesh implant was performed. Our approach was to delay stoma closure until complete healing of the abdominal wound, avoiding a contaminated procedure (stoma closure and anastomosis) together with a mesh implant.

In cases of extensive loss of the abdominal wall, regardless of the primary reason, and in line with the literature, intra-abdominal NPWT following surgical debridement represents a modern strategy for improving outcomes, obtaining good results, and containing costs of treatment.^[8]

In conclusion, large IH in obese patients should better be treated in elective conditions since the occurrence of complications, as the one observed in this case, may have a misleading clinical presentation. The resulting delay in treatment ends up in a complex picture, requiring specialized expertise and many different treatments. However, an aggressive and accurate approach like that employed in this case warrants good results.

Author contribution

We certify that we have participated sufficiently in the intellectual content, conception and design of this work or the analysis and interpretation of the data (when applicable), as well as the writing of the manuscript, to take public responsibility for it and have agreed to have our name listed as a contributor.

Ethical policy and Institutional Review Board statement

The case described has been managed in compliance with applicable regulatory requirements, good clinical practice and ethical principles in accordance with the Declaration of Helsinki.

Declaration of patient consent

The authors certify that they have obtained all appropriate patient consent forms. In the form, the patient(s) has/have given his/her/their consent for his/her/their images and other clinical information to be reported in the journal. The patients understand that their names,

and initials will not be published, and due efforts will be made to conceal their identity, but anonymity cannot be guaranteed.

Data availability statement

The datasets generated during and/or analyzed during the current study are available from the corresponding author on reasonable request.

Financial support and sponsorship

Nil.

Conflicts of interest

There are no conflicts of interest.

Acknowledgments

Not applicable.

References

1. Hope WW, Tuma F. Incisional hernia. In: StatPearls. Treasure Island, FL: StatPearls Publishing; 2024. Available from the website of NCBI.
2. Cervantes BYH, Acevedo FA, Lopez DM, Lambert RG, Gonzalez MR. Our first Pfannenstiel incisional hernia: A case report. *J Surg Case Rep* 2022;2022:rjac546.
3. Martis JJ, Shridhar KM, Rajeshwara KV, Janardhanan D, Jairaj D. Spontaneous rupture of incisional hernia – A case report. *Indian J Surg* 2011;73:68-70.
4. Van Ramshorst GH, Eker HH, Harlaar JJ, Nijens KJ, Jeekel J, Lange JF. Therapeutic alternatives for burst abdomen. *Surg Technol Int* 2010;19:111-9.
5. Suliburk JW, Ware DN, Balogh Z, McKinley BA, Cocanour CS, Kozar RA, *et al.* Vacuum-assisted wound closure achieves early fascial closure of open abdomens after severe trauma. *J Trauma* 2003;55:1155-60; discussion 1160.
6. Pillay P, Smith MTD, Bruce JL, Clarke DL, Bekker W. The efficacy of VAMMFT compared to “Bogota Bag” in achieving sheath closure following temporary abdominal closure at index laparotomy for trauma. *World J Surg* 2023;47:1436-41.
7. Condé-Green A, Chung TL, Holton LH, Hui-Chou HG, Zhu Y, Wang H, *et al.* Incisional negative-pressure wound therapy versus conventional dressings following abdominal wall reconstruction: A comparative study. *Ann Plastic Surg* 2013;71:394-7.
8. Cirocchi R, Birindelli A, Biffl WL, Mutafchiyski V, Popivanov G, Chiara O, *et al.* What is the effectiveness of the negative pressure wound therapy (NPWT) in patients treated with open abdomen technique? A systematic review and meta-analysis. *J Trauma Acute Care Surg* 2016;81:575-84.