

Access this article online

Quick Response Code:



Website:

www.herniasurgeryjournal.org

DOI:

10.4103/ijawhs.ijawhs_78_24

A bibliometric analysis of Nuck canal cyst research

Muhammed Salih Süer, Gamze Kızıltan

Abstract

BACKGROUND: Nuck canal cysts, or the hydrocele of the canal of Nuck, are rare conditions primarily affecting females. Over the past two decades, research interest in this area has increased, leading to a growing number of scientific publications. This bibliometric analysis aims to evaluate the trends in scientific publications related to Nuck canal cysts, identify leading contributors, and understand the global research landscape.

MATERIALS AND METHODS: A comprehensive literature search on PubMed using the terms “Nuck canal cyst,” “canal of Nuck,” and “female hydrocele” was conducted. Limited to English-language articles and reviews published since 2000, the search concluded on July 5, 2024, yielded 166 relevant articles. After a review by two independent authors, 21 articles were deemed irrelevant, leaving 145 articles for further analysis.

RESULTS: The annual scientific research production showed a significant increase in publications from 2011 onward, peaking around 2021. Leading institutions included Fujita Health University Okazaki Medical Center, Kurume University School of Medicine, and Sapporo Higashi Tokushukai Hospital. The USA, Japan, and Turkey emerged as the top contributing countries, with Japan leading in the number of overall publications.

CONCLUSION: There has been a notable increase in research studies on Nuck canal cysts over the past decade, with significant contributions from specific institutions and countries. This growing body of research underscores the increasing interest and advancements in understanding, diagnosing, and treating Nuck canal cysts. Future research should continue to build on this foundation, exploring new diagnostic techniques, treatment options, and long-term patient outcomes.

Keywords:

Female, hydrocele, inguinal hernia, Nuck cyst, ultrasound

Introduction

Nuck canal cysts, also known as hydroceles of the canal of Nuck, are a rare condition affecting females, characterized by a fluid-filled sac in the inguinal region due to the incomplete obliteration of the Nuck canal. This uncommon presentation is primarily observed in females and is often misdiagnosed or underreported, contributing to a limited understanding within the medical community. Despite its clinical significance, publications on Nuck canal cysts remain sparse and scattered, with few comprehensive reviews or guidelines

to standardize diagnosis and management. Given the fragmented and insufficient nature of the existing literature, a bibliometric analysis focused on Nuck canal cysts offers a valuable tool to systematically map out the current research landscape, identifying key contributors and uncover patterns and gaps in knowledge. Such an analysis can ultimately enhance the understanding of this rare entity, providing a foundation for more consistent and informed approaches to diagnosis and treatment in clinical practice.

Nuck canal cysts are characterized by the persistence of the processus vaginalis in females, resulting in the formation of a fluid-filled cyst in the inguinal region.

This is an open access journal, and articles are distributed under the terms of the Creative Commons Attribution-NonCommercial-ShareAlike 4.0 License, which allows others to remix, tweak, and build upon the work non-commercially, as long as appropriate credit is given and the new creations are licensed under the identical terms.

For reprints contact: WKHLRPMedknow_reprints@wolterskluwer.com

How to cite this article: Süer MS, Kızıltan G. A bibliometric analysis of Nuck canal cyst research. *Int J Abdom Wall Hernia Surg* 2025;8:35-43.

Department of General Surgery, Etlik City Hospital, Ankara, Turkey

Address for correspondence:

Dr. Muhammed Salih Süer, General Surgery Clinics, Etlik City Hospital, Yenimahalle, Ankara 06200, Turkey.
E-mail: suersalih@gmail.com

Submitted: 23-Oct-2024

Revised: 18-Nov-2024

Accepted: 30-Nov-2024

Published: 26-Mar-2025

Despite being relatively uncommon, an understanding of the epidemiology, diagnosis, and treatment of Nuck canal cysts is crucial for effective management. Nuck canal cysts are observed primarily in females due to the anatomical structure of the Nuck canal, which is analogous to the processus vaginalis in males.^[1] The condition is rare, with few cases reported in the literature. It often presents in pediatric patients but can also be seen in adult women. The true incidence is likely underreported due to the asymptomatic nature of many cases and the potential for misdiagnosis.

Patients with Nuck canal cysts typically present with a painless, reducible swelling in the inguinal or labial region. The swelling may increase in size over time and can occasionally cause discomfort. Differential diagnoses include inguinal hernia, lymphadenopathy, and other cystic formations such as Bartholin's cysts.^[2]

Ultrasound is the primary imaging modality used to diagnose Nuck canal cysts. It helps differentiate the cyst from other inguinal masses and provides details about the cyst's size, location, and content.^[3] Magnetic resonance imaging (MRI) can be employed in ambiguous cases to provide more detailed anatomical information.

Histopathological examination post-surgical excision confirms the diagnosis. The cyst containing serous fluid is lined with mesothelial cells. The presence of smooth muscle fibers in the cyst wall can also be noted.^[4]

It is possible that asymptomatic Nuck canal cysts may not require immediate intervention. It may be advisable to consider regular follow-up to monitor for any changes in size or symptomatology. Surgical excision may be considered the definitive treatment for symptomatic Nuck canal cysts. The procedure involves careful dissection and removal of the cyst, while preserving surrounding structures. Laparoscopic surgery is an emerging minimally invasive option that may offer faster recovery times and reduced postoperative complications.^[5]

It is important to note that untreated Nuck canal cysts can potentially lead to complications such as infection, rupture, and the development of inguinal hernias. Although surgical complications, including infection, hematoma, and injury to surrounding structures, are relatively rare with experienced surgeons, it is still important to be aware of the potential risks involved.^[6]

The bibliometric approach provides a comprehensive methodology for the analysis of literature, enabling an understanding of the development of a specific field by examining the relationships within the literature. This approach allows us to uncover research hotspots and predict future trends through data analysis and

visualization.^[7] The objective of this study is to forecast future research directions and identify key areas of interest by analyzing literature from the PubMed database.

Materials and Methods

Source and retrieval strategy for literature

A comprehensive literature search was conducted on the PubMed database using the following search terms: "Nuck canal cyst," "canal of Nuck," and "female hydrocele." The search was limited to English-language publications and articles and reviews published since 2000. The type of literature was set to articles and reviews, covering the entire period from the beginning of the search up to the present. To ensure consistency and avoid discrepancies due to database updates, the search was completed on July 5, 2024. A total of 166 relevant articles were identified.

A total of 166 articles were subjected to a comprehensive review by two independent authors. Following this process, 21 articles were excluded as being irrelevant, resulting in a total of 145 articles remaining for further analysis.

Data analysis

The study used Microsoft Excel 2020 to analyze annual publication trends and organize the data. For more advanced analyses, the Bibliometrix package in R was employed to construct relational network maps, perform cluster analyses, and conduct emergent word analysis. This entailed mapping the relationships between countries, institutions, authors, and keywords in the selected samples to gain insights into current research status and trends in the field. The visualization maps display each node, representing a different entity within the network. The retrieval and analysis strategy are illustrated in Figure 1.

Clinical trial registry

Not applicable.

Results

Annual scientific production

The analysis of annual scientific research production shows a general increase in the number of publications from 2000 to 2023. Figure 2 illustrates the number of articles published per year. It demonstrates a notable surge in annual publications following 2013, with 16 publications per year being reached in 2020 and 2022. As evidenced by the data presented in this table, there has been a notable upward trend in recent years. As illustrated in Figure 3, the number of publications has increased in recent years, with Japan, the USA, and Italy demonstrating particularly notable growth.

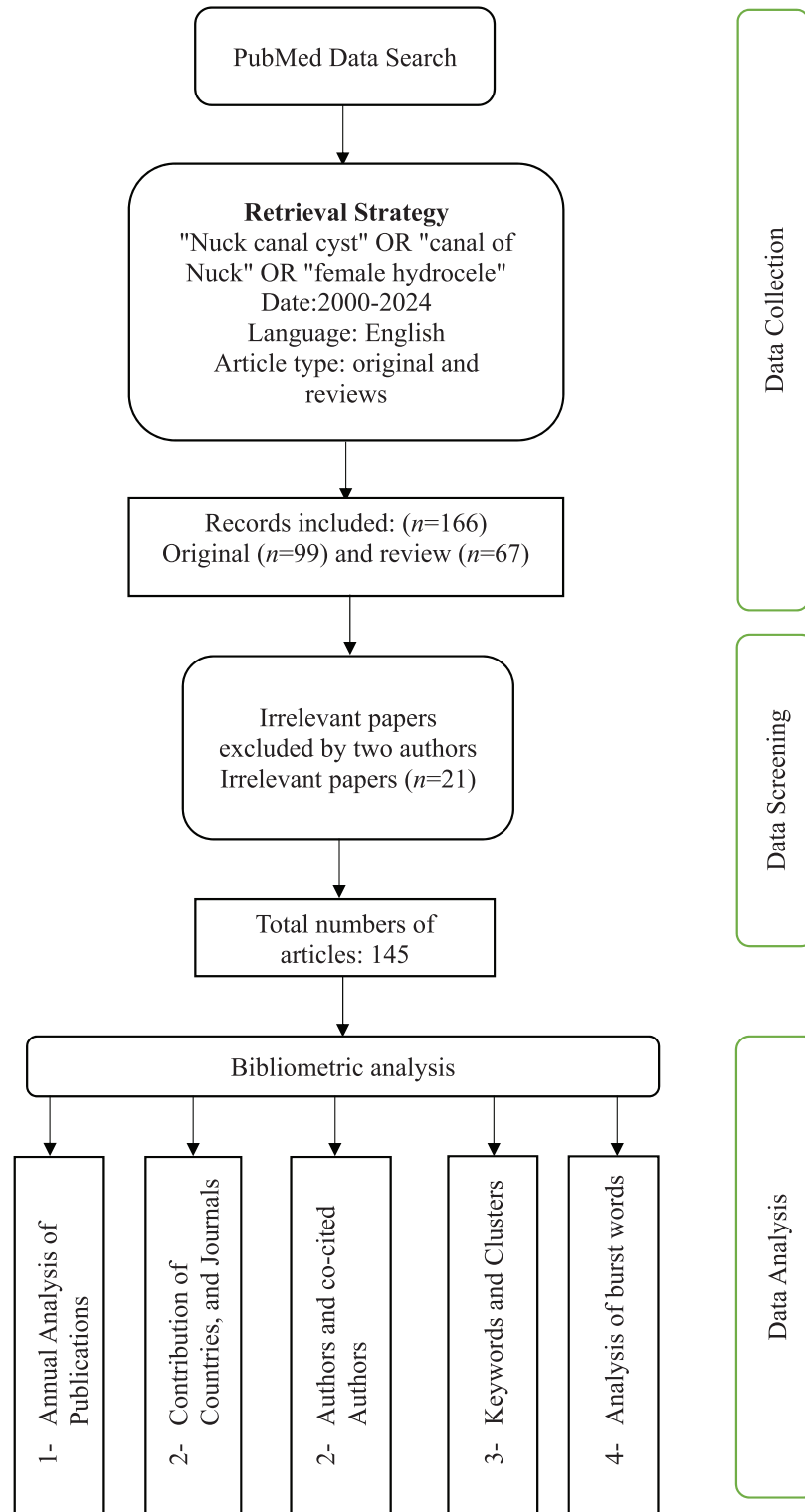


Figure 1: Flowchart illustrating the literature search process for the bibliometric analysis of Nuck canal cyst research, including the identification, screening, eligibility, and inclusion stages

Contribution of countries, institutions, and journal

The data highlight several key institutions and countries that have made significant contributions to the research on Nuck canal cysts. Leading institutions such as Fujita

Health University Okazaki Medical Center, Kurume University School of Medicine, and Sapporo Higashi Tokushukai Hospital have been pivotal in advancing our understanding of this condition. These institutions' contributions are crucial in fostering a collaborative

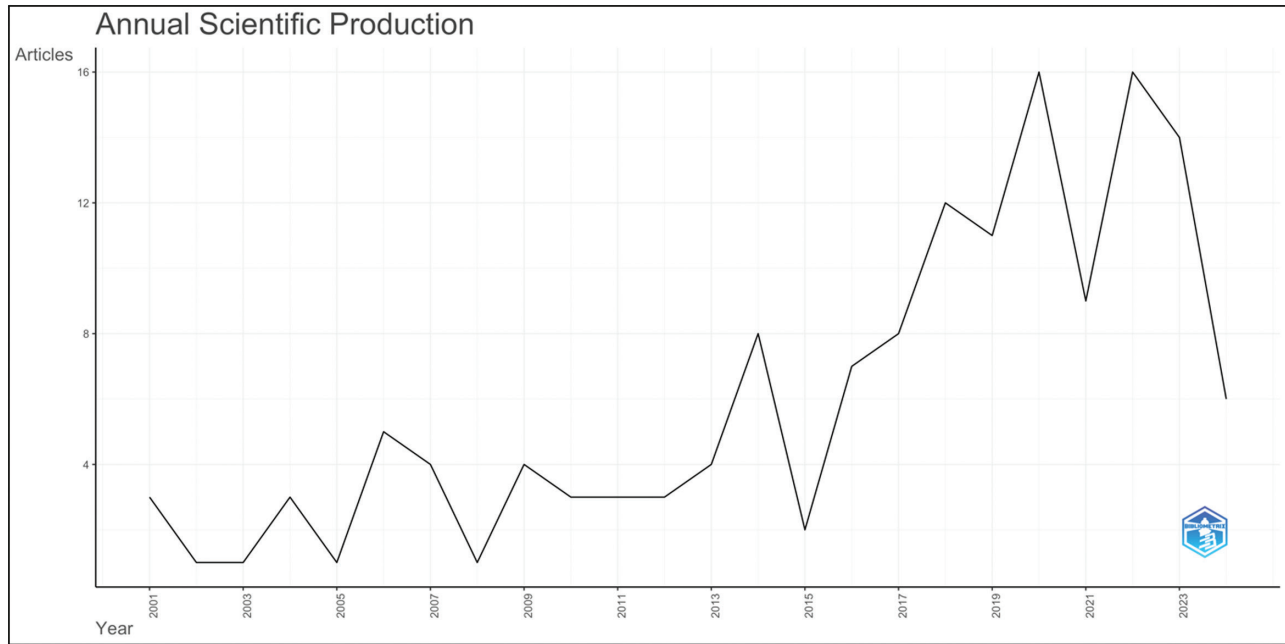


Figure 2: Annual scientific production

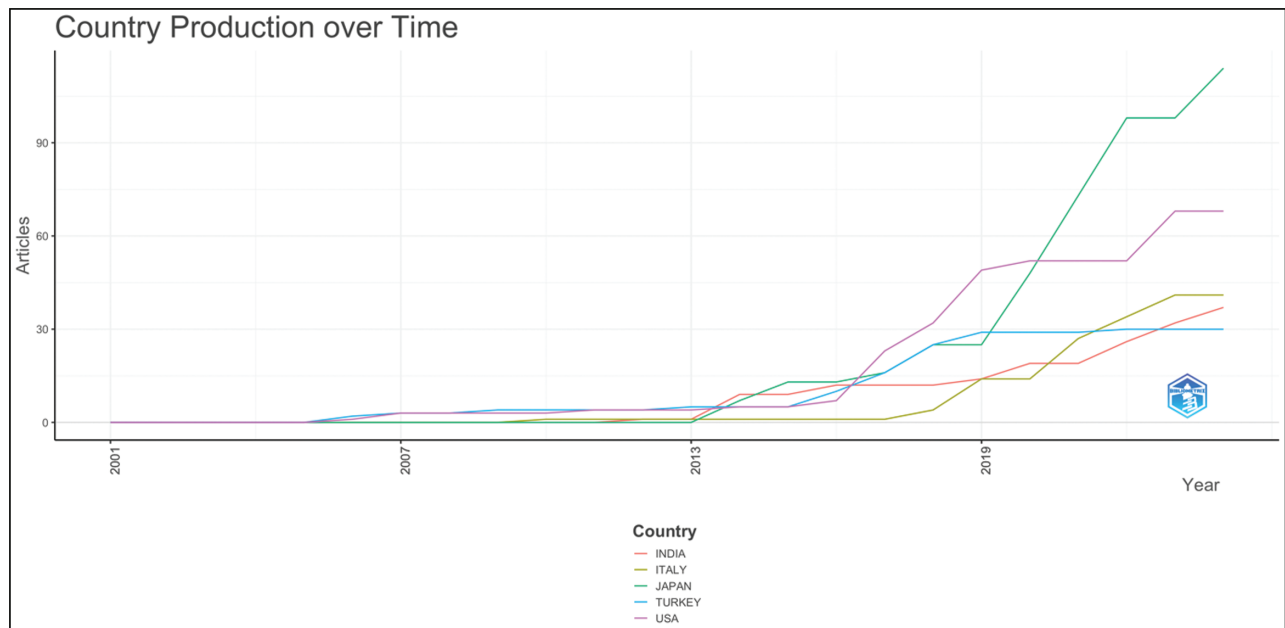


Figure 3: Country production over time

research environment and enhancing the dissemination of knowledge.

Geographically, Japan, the USA, and Turkey emerge as the top contributors to this field. Japan being the biggest contributor to overall publications may be attributed to a combination of robust research infrastructure, funding, and academic interest. The USA's significant contributions reflect its extensive research capabilities and emphasis on medical research. Turkey's notable research activity underscores its growing role in global

medical research, particularly in specialized fields such as Nuck canal cysts.

Upon examination of the number of publications by affiliation [Figure 4], it was observed that the aggregate number of publications from the three leading Japanese institutions (Kurume University School of Medicine, Sapporo Higashi Tokushukai Hospital, and Fujita Health University Okazaki Medical Center) was 38 [Figure 5]. These institutions have shown significant research activity, especially since 2019.

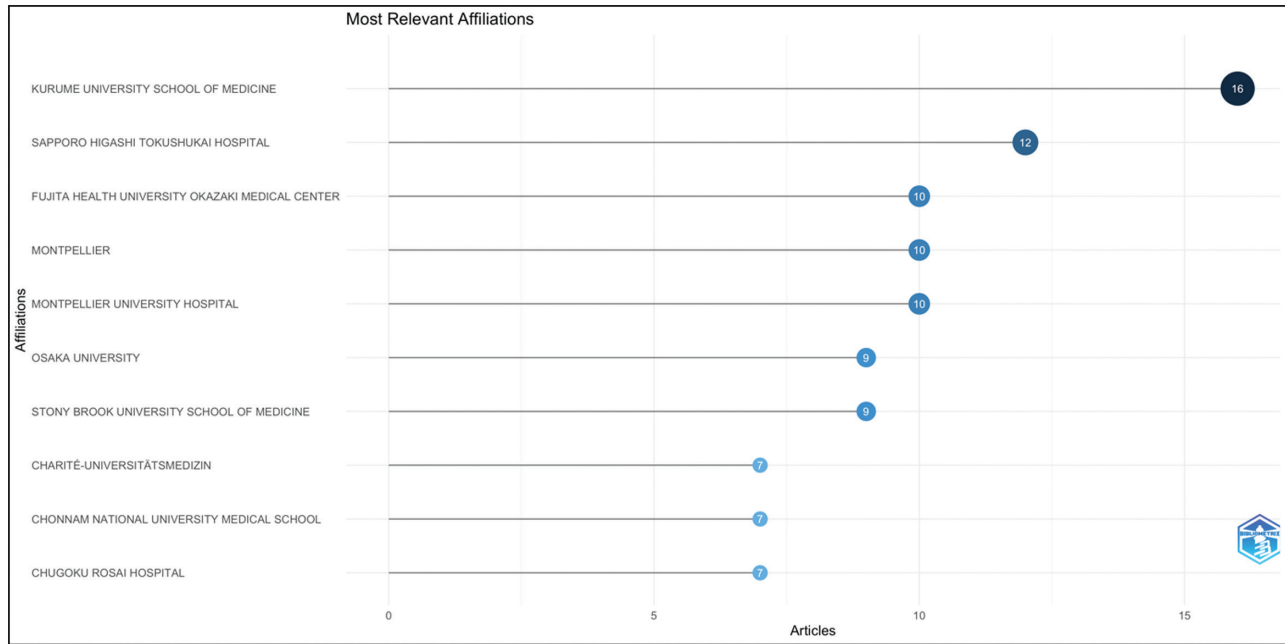


Figure 4: Most relevant affiliations

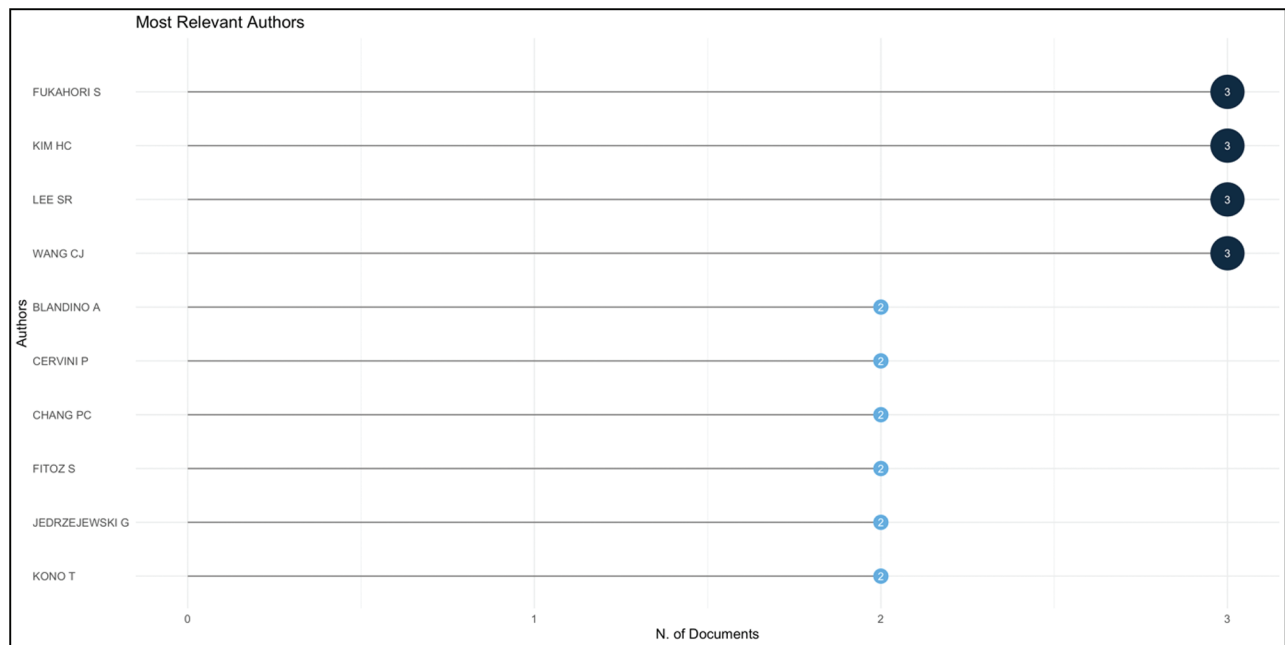


Figure 5: Most relevant authors

Key institutions contributing to the research on Nuck canal cysts include the following:

- Fujita Health University Okazaki Medical Center.
- Kurume University School of Medicine.
- Sapporo Higashi Tokushukai Hospital.
- Montpellier.

Research on Nuck canal cysts is predominantly conducted in developed countries, with notable contributions from the following:

- Japan: Leading in overall publications.
- USA: Following closely behind Japan.
- Turkey: Also showing significant research activity.
- India and Italy: Contributing notably from 2016 onward.

The analysis of the most relevant sources for publications on Nuck canal cysts highlights the key journals contributing to this field [Figure 6]. The International Journal of Surgery Case Reports leads with nine documents, reflecting its prominence in disseminating case-based surgical research. Other significant

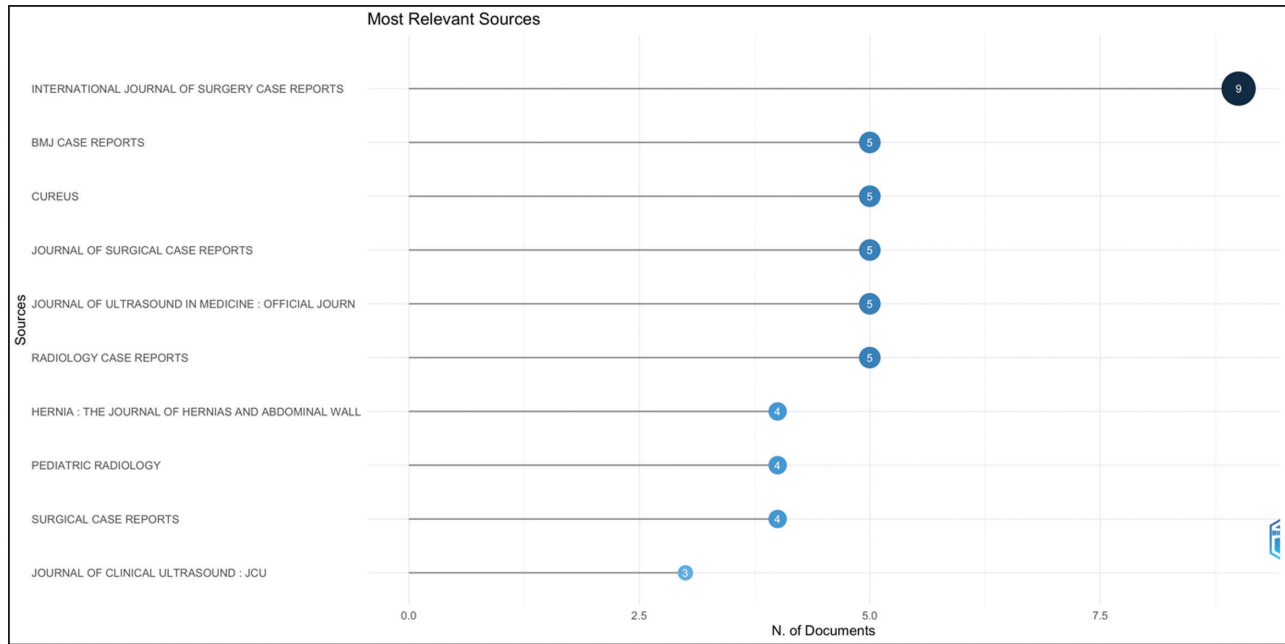


Figure 6: Most relevant sources

contributors include BMJ Case Reports, Cureus, Journal of Surgical Case Reports, and the Journal of Ultrasound in Medicine, each with five documents, indicating their substantial roles in reporting clinical findings and imaging studies related to Nuck canal cysts. Further notable sources are Radiology Case Reports, Hernia: The Journal of Hernias and Abdominal Wall, Pediatric Radiology, and Surgical Case Reports, each contributing four documents. The Journal of Clinical Ultrasound rounds out the list with three documents, emphasizing the importance of ultrasound in the diagnosis and management of Nuck canal cysts. This distribution underscores the diverse range of journals that publish research on this rare condition, highlighting the multidisciplinary interest and the importance of case reports in advancing the clinical understanding.

Keywords analysis

The examination of the most pertinent keywords in research on Nuck canal cysts offers insights into the principal foci and themes within this field. The keyword “humans” is the most frequently occurring, with 81 instances, which serves to underscore the emphasis on human studies. “Female” is closely followed with 75 occurrences, which aligns with the fact that Nuck canal cysts predominantly affect females. The term “adult” is referenced 37 times, indicating a notable interest in cases affecting adults, although Nuck canal cysts have also been observed in pediatric populations [Figure 7].

The term “diagnosis differential” is of particular significance, appearing 28 times in the analysis. This

reflects the importance of distinguishing Nuck canal cysts from other conditions. The term “male” appears 22 times, indicating a potential interest in comparative studies or case reports involving male subjects. The term “ultrasonography,” with 17 occurrences, highlights the pivotal role of ultrasound in diagnosing Nuck canal cysts. Other relevant keywords include “child” (16 occurrences) and “infant” (14 occurrences), which indicate a focus on pediatric cases. The term “treatment outcome” is mentioned 12 times, indicating a focus on evaluating the effectiveness of various treatment modalities. Additionally, the term “inguinal canal/surgery” is mentioned 11 times, underscoring the surgical aspects and the anatomical location pertinent to Nuck canal cysts. The collective use of these keywords provides a comprehensive overview of the research landscape, emphasizing epidemiology, diagnosis, demographics, and treatment outcomes [Figure 8].

The word cloud offers a visual representation of the most frequently utilized terminology in research articles pertaining to Nuck canal cysts [Figure 9]. The most prominent terms are “humans,” “female,” and “diagnosis differential,” which collectively represent the most common keywords in the literature. The terms “humans” and “female” are of particular significance, reflecting the fact that the condition predominantly affects females. Other noteworthy terms include “adult,” “male,” and “treatment outcome.” The aforementioned keywords imply a concentration on adult and male comparisons, the utilization of ultrasound as a diagnostic instrument, and an accentuation on the evaluation of treatment outcomes.

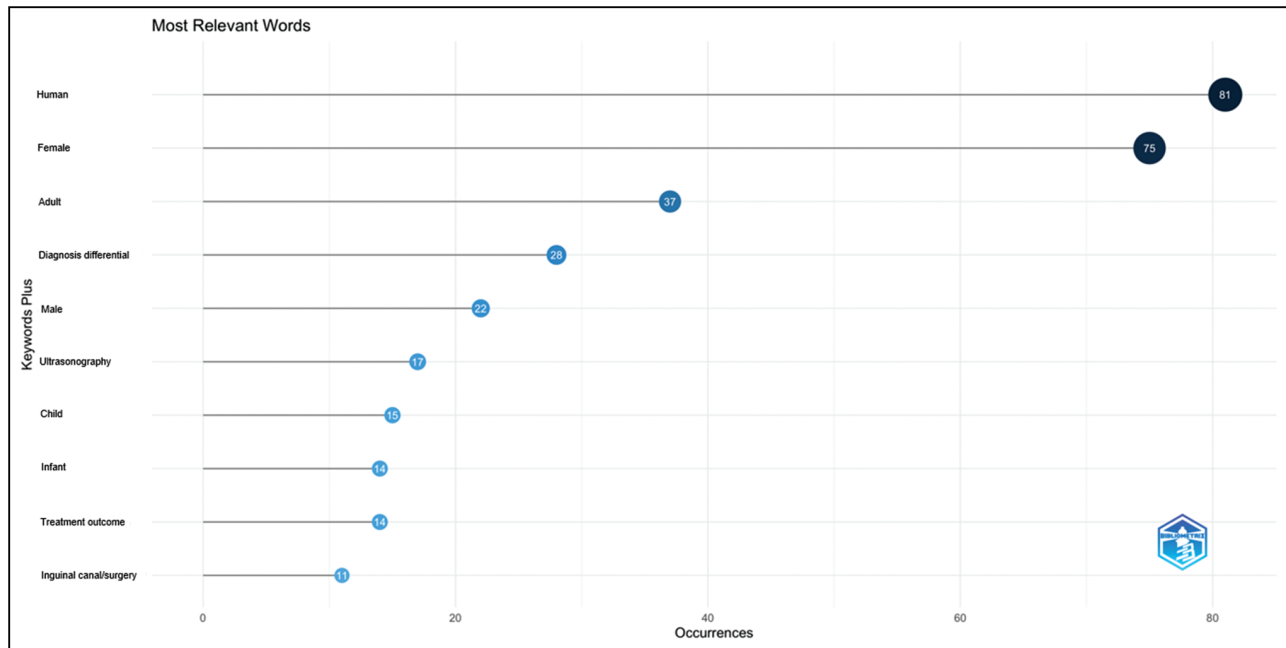


Figure 7: Most relevant words




Figure 8: Word cloud of Nuck canal cyst

The prominence of terms such as “inguinal canal/surgery,” “laparoscopy,” and “magnetic resonance imaging,” “ultrasonography,” and “tomography” underscores the pivotal role of imaging techniques and surgical interventions in the diagnosis and treatment of Nuck canal cysts. The appearance of additional terms, including “child,” “infant,” “middle aged,” and “retrospective studies,” suggests the inclusion of a diverse range of demographic studies and diagnostic techniques in the research. In summary, the word cloud encapsulates the key themes and areas of focus within the research on Nuck canal cysts, providing a rapid and comprehensive overview of the field.

Discussion

This bibliometric analysis identifies significant trends in the research on Nuck canal cysts over the past two decades. The increasing number of publications, especially after 2013, reflects a growing interest and advancements in diagnostic imaging techniques, notably ultrasound and MRI, which have enhanced the identification and differentiation of these cysts.

Japan, the United States of America, and Turkey have made the greatest contributions to this field of study. In particular, institutions such as Fujita Health University

excluding influential research in other languages or databases. This may introduce bias by omitting significant contributions from non-English-speaking regions. Second, although the Bibliometrix package in R is powerful, it may not fully capture emerging research trends as recent publications might lack sufficient citations. Third, relying on two independent authors for initial review and exclusion of irrelevant articles introduces subjectivity and potential bias. It would be beneficial for future studies to consider a more automated, standardized approach and include a broader range of sources and languages for a more comprehensive understanding of the field.

Author contributions

MSS: Conceptualization, methodology, data collection, analysis, and manuscript writing.
GK: Data validation, manuscript review, and editing.

Ethical policy and institutional review board statement

Not applicable.

Data availability statement

The datasets generated during and/or analyzed during the current study are available from the corresponding author on reasonable request.

Financial support and sponsorship

Nil.

Conflicts of interest

There are no conflicts of interest.

Acknowledgements

We would like to acknowledge that there are no conflicts of interest or financial disclosures related to this study. No ethical approval was required due to the nature of the study. Authors participated equally in conception, research, and writing.

References

1. Papparella A, Vaccaro S, Accardo M, Rosa LDE, Ronchi A, Noviello C. Nuck cyst: A rare cause of inguinal swelling in infancy. *Minerva Pediatr (Torino)* 2021;73:180-3.
2. Kohlhauser M, Pirsch JV, Maier T, Viertler C, Fegerl R. The cyst of the canal of Nuck: Anatomy, diagnostic and treatment of a very rare diagnosis-A case report of an adult woman and narrative review of the literature. *Medicina (Kaunas)* 2022;58:1353.
3. Bazuaye-Ekwuyasi E, Odogwu-Hall O, Bushey H, Camacho A, Bhargava P. Multimodality imaging features of canal-of-nuck hydrocele in adults. *Clin Imaging* 2022;92:101-8.
4. Nasser H, King M, Rosenberg HK, Rosen A, Wilck E, Simpson WL. Anatomy and pathology of the canal of Nuck. *Clin Imaging* 2018;51:83-92.
5. Tominaga M, Morikawa K, Ogawa Y, Kamimura N, Tsuneki I, Tamura M, *et al.* Laparoscopic surgery for a hydrocele of the canal of Nuck with an ovarian tumor: An extremely rare clinical finding. *Clin Case Rep* 2022;10:e05320.
6. Tilva H, Tayade S, Kanjiya A. Contemporary review of masses in the canal of nuck. *Cureus* 2023;15:e36722.
7. Chen C, Song M. Visualizing a field of research: A methodology of systematic scientometric reviews. *PLoS One* 2019;14:e0223994.