



Duodenum in the right hemithorax: An unusual case of a large paraesophageal hernia

Mahisha Viridiana¹, Vijayendra Kedage², Manasa Ubarale², K. Rajgopal Shenoy²

Abstract

Paraesophageal hernia is an uncommon condition where the gastric fundus herniates through the diaphragm without the accompanied migration of the gastroesophageal junction. A woman in her late 60s presented with symptoms of vomiting and decreased appetite for 1 year, accompanied by abdominal fullness in the epigastrium, nausea, and retrosternal burning sensation. Her symptoms worsened over the past month, leading to intolerance to a liquid diet. Upon examination, a vague, tender mass was palpated over the epigastrium, and decreased breath sounds were noted over the right hemithorax. Computed tomography suggested the presence of paraesophageal hernia. An exploratory laparotomy was performed. Intraoperatively, a 4 cm paraesophageal diaphragmatic defect was found through which the antrum and the first part of the duodenum had herniated. The hernial contents were reduced, and anatomical closure was performed. Paraesophageal hernias necessitate careful history and examination, along with an individualized treatment approach, to achieve optimal patient outcomes.

Keywords:

Hernia, hiatal hernia, large paraesophageal hernia, paraesophageal hernia

Introduction

Paraesophageal hernia is an uncommon subtype of hiatal hernias, wherein organs of the abdominal cavity herniate into the mediastinum through defects in the diaphragmatic hiatuses. A “true” paraesophageal hernia is a condition in which the gastric fundus herniates through the diaphragm while the gastroesophageal junction (GEJ) remains abdominal.^[1] Here, we discuss a patient with a paraesophageal hernia containing the duodenum, along with features indicative of gastric outlet obstruction.

Case Report

We present a case of a woman in her late 60s with hypertension, type 2 diabetes mellitus,

and hypothyroidism, who presented to the outpatient department with complaints of vomiting and decreased appetite for 1 year. The vomitus contained food particles and was neither blood-stained nor bilious. These symptoms were accompanied by abdominal fullness in the epigastric region, nausea, and a retrosternal burning sensation. Over the past month, she had experienced worsening symptoms, leading to an inability to tolerate a liquid diet. She reported previous use of proton pump inhibitors for the same complaints, prescribed by her general physician. There were no complaints of loose stools, constipation, breathlessness, or similar symptoms before this 1-year period.

On examination, pallor was noted. Her Body Mass Index was 29.8 kg/m². Respiratory system examination revealed decreased breath sound amplitude over the right lung

This is an open access journal, and articles are distributed under the terms of the Creative Commons Attribution-NonCommercial-ShareAlike 4.0 License, which allows others to remix, tweak, and build upon the work non-commercially, as long as appropriate credit is given and the new creations are licensed under the identical terms.

For reprints contact: WKHLRPMedknow_reprints@wolterskluwer.com

How to cite this article: Viridiana M, Kedage V, Ubarale M, Shenoy KR. Duodenum in the right hemithorax: An unusual case of a large paraesophageal hernia. *Int J Abdom Wall Hernia Surg* 2024;7:184-8.

¹Kasturba Medical College of Manipal, Manipal Academy of Higher Education, Manipal, Karnataka, India,

²Department of General Surgery, Kasturba Medical College of Manipal, Manipal Academy of Higher Education, Manipal, Karnataka, India

Address for correspondence:

Dr. Mahisha Viridiana,
Kasturba Medical College of Manipal, Manipal Academy of Higher Education, Tiger Circle Road, Madhav Nagar, Eshwar Nagar, Manipal, Udipi, Karnataka-576104, India.
E-mail: mahishavms@gmail.com

Submitted: 03-Jan-2024

Revised: 05-Mar-2024

Accepted: 19-Mar-2024

Published: 07-Aug-2024

fields. Abdominal examination revealed a distension in the epigastrium upon inspection. A vague, diffuse, tender mass was palpated. The umbilicus was centrally located, and bowel sounds were present. Cardiovascular and nervous system examinations were normal. A provisional diagnosis of gastric outlet obstruction was considered. An attempt to pass a nasogastric tube was successful.

Routine lab investigations revealed a hemoglobin level of 11.1 g/dl, a urea level of 12 mg/dl, and a sodium level of 131 mmol/L. A chest X-ray revealed a large air-fluid level occupying the right hemithorax [Figure 1A]. A plain and contrast CT of the abdomen and pelvis demonstrated a grossly overdistended stomach with the distal part of the body, antrum, pylorus, and proximal duodenum appearing to be displaced upward, herniating into the posterior mediastinum through the esophageal hiatus. Subsegmental collapse of the underlying lung was noted, suggestive of a paraesophageal hernia with stomach as the content. There was displacement of the antrum above the GEJ, and the stomach appeared upside-down, with the antrum and pylorus superior to the fundus and proximal body [Figure 2]. Upper gastrointestinal endoscopy was done twice after ruling out gastric volvulus due to suspicion of possible malignancy leading to anemia and gastric outlet obstruction. However, gastric mucosa could not be visualized due to retained food particles.

The patient underwent exploratory laparotomy. Intraoperatively, an enlarged stomach with a paraesophageal diaphragmatic defect of 4 cm, containing the distal stomach and the first part of duodenum, was found [Figures 3 and 4]. There was no evidence of gastric volvulus. Reduction of the paraesophageal hernia and anatomic closure of the

defect with interrupted No. 1 prolene was performed, which was well tolerated by the patient. The operation lasted 1.5 h. The post-operative period was uneventful, and the patient was started on oral feeds by post-operative day 2, after which she passed stools. A repeat chest X-ray was normal [Figure 1B]. The patient was lost to follow-up but presented to our outpatient department 3 years later with a midline incisional hernia.

Discussion

Landreneau *et al.*^[2] subdivided hiatal hernias into four types, based on their anatomy. The most commonly occurring hiatal hernias are type I hiatal hernias, known as the sliding hiatal hernia. They are characterized by the migration of the GEJ through the esophageal hiatus. Type II hiatal hernias are paraesophageal hernias, also known as rolling hernias. They account for approximately 5% of hiatal hernias and are categorized by the conservation of the intra-abdominal position of the GEJ, with the hiatal sac typically containing the gastric fundus. In our patient, the hernial sac contained the gastric pylorus and the first part of the duodenum, which is a rare presentation. A combination of types I and II give rise to type III hiatal hernia, wherein the stomach along with the GEJ migrate superiorly into the mediastinum. Type IV is a complex or giant paraesophageal hiatal hernia, characterized by the herniation of other abdominal organs such as the omentum, spleen, pancreas, liver, small bowel, and colon into the thorax.^[2,3]

The clinical presentation of paraesophageal hernias varies widely. Many patients experience vague symptoms that are often attributed to more prevalent conditions like gastritis, anxiety, and gallstone disease. Patients report symptoms such as chest or upper abdominal discomfort,

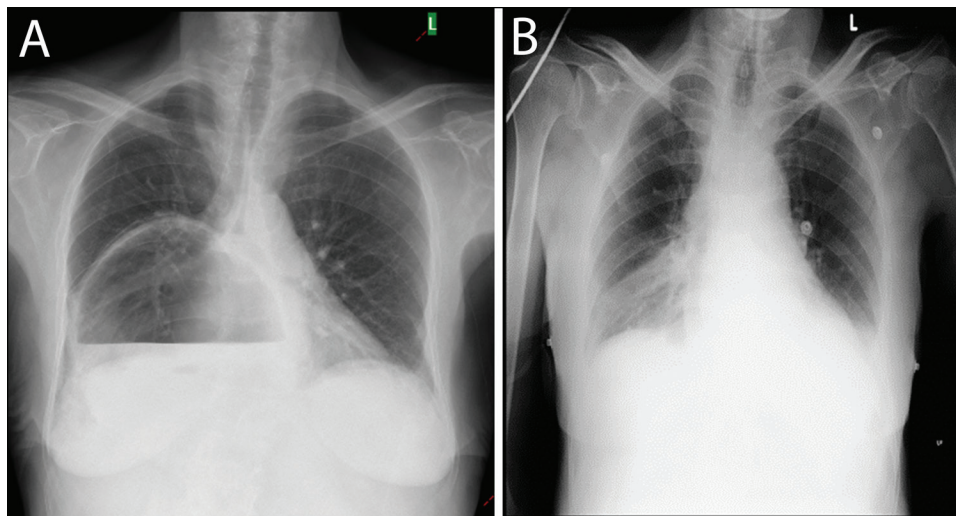


Figure 1: (A) Preoperative chest X-ray showing a large air-fluid level occupying the right hemithorax. (B) Post-operative normal chest X-ray following successful repair

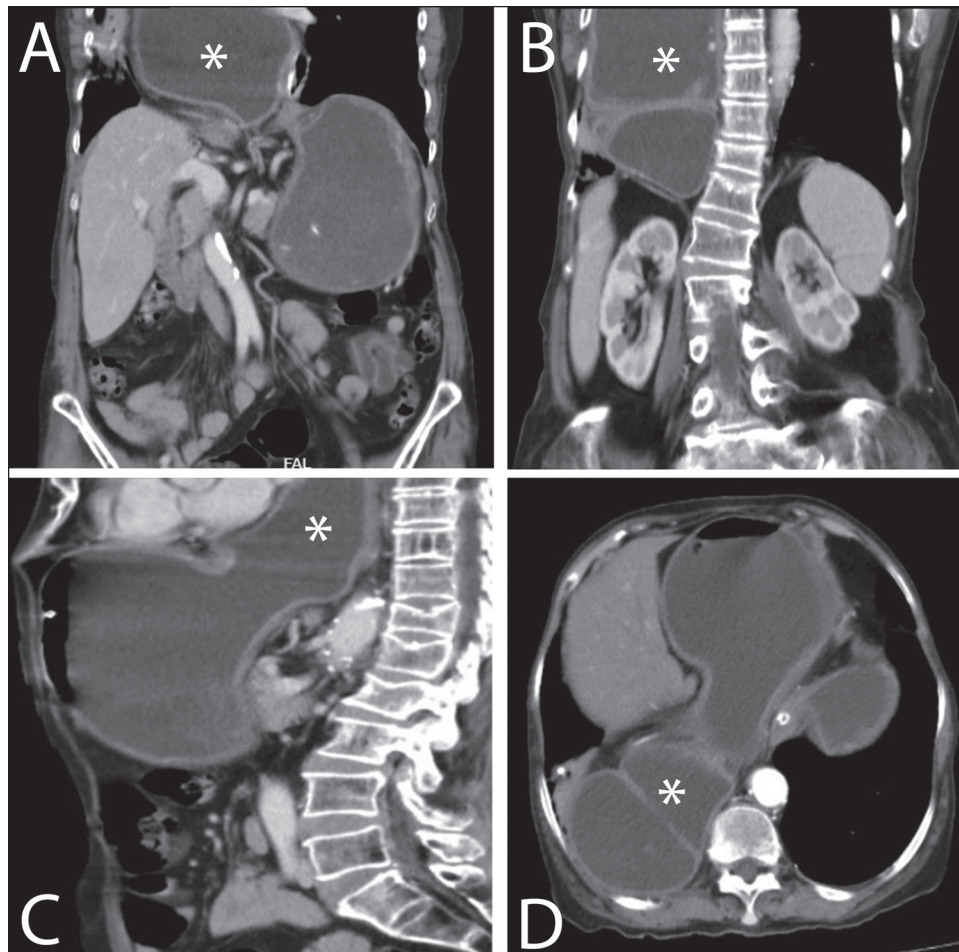


Figure 2: Computed tomography sections in different views showing the duodenum (marked as asterisk) in the right hemithorax. (A and B) Coronal view. (C) Sagittal view. (D) Axial view

heartburn, regurgitation, abdominal fullness, nausea, or dysphagia, which arise from anatomic distortion and increased intra-esophageal pressure. Microcytic anemia is also reported, believed to stem from gastric mucosal erosions due to crural pressure, termed “Cameron’s ulcers.” Our patient similarly presented with a long-standing history of vague abdominal symptoms, with anemia detected during routine investigations.^[4] Larger hernias can also lead to dyspnea and pulmonary aspiration, which may progress to recurrent pulmonary infections. These infections are often treated with repetitive courses of antibiotics.^[5]

In contrast to non-specific symptomatology, patients with paraesophageal hernias may also present with acute complications such as gastric outlet obstruction or stomach strangulation secondary to gastric volvulus.^[6-8] The primary cause of mortality in patients with large paraesophageal hernias is the consequence of ischemia resulting from stomach strangulation, which can subsequently lead to stomach perforation and spillage of its contents into the mediastinum. Seventy percent of such patients present with what is known as

Borchardt’s triad—failure to pass a nasogastric tube, the inability to vomit accompanied by retching, and severe epigastric pain.^[8] Epigastric pain may be accompanied by radiation of pain to the left shoulder, caused by internal hemorrhage or gastric contents irritating the diaphragm.^[4]

The diagnostic workup for a paraesophageal hernia includes imaging modalities such as CT of the thorax and abdomen, barium swallow with a gastrointestinal contrast series, and upper gastrointestinal endoscopy, especially in patients presenting with anemia.^[9] Physiology tests of the esophagus such as manometry, are not recommended as increased intraluminal pressure is attributable to the anatomical distortion.^[10]

Owing to the vast spectrum of possible presentations and lack of a standardized operative protocol, each case must be assessed individually, with treatment plans tailored accordingly. Many patients with this condition are elderly, with a higher prevalence of comorbidities, and hence may not be an ideal demographic for surgical repair. Asymptomatic patients with small defects may

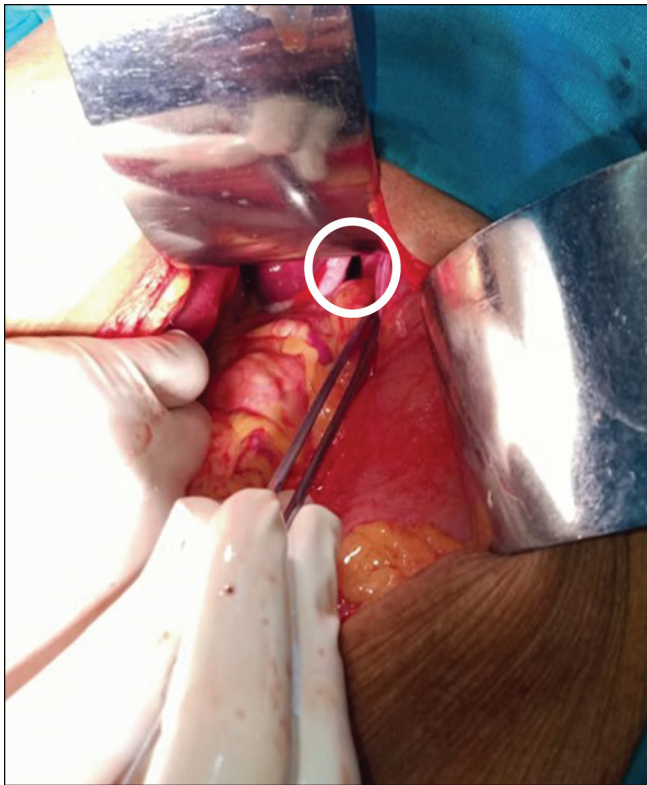


Figure 3: A 4 cm paraesophageal defect found intraoperatively

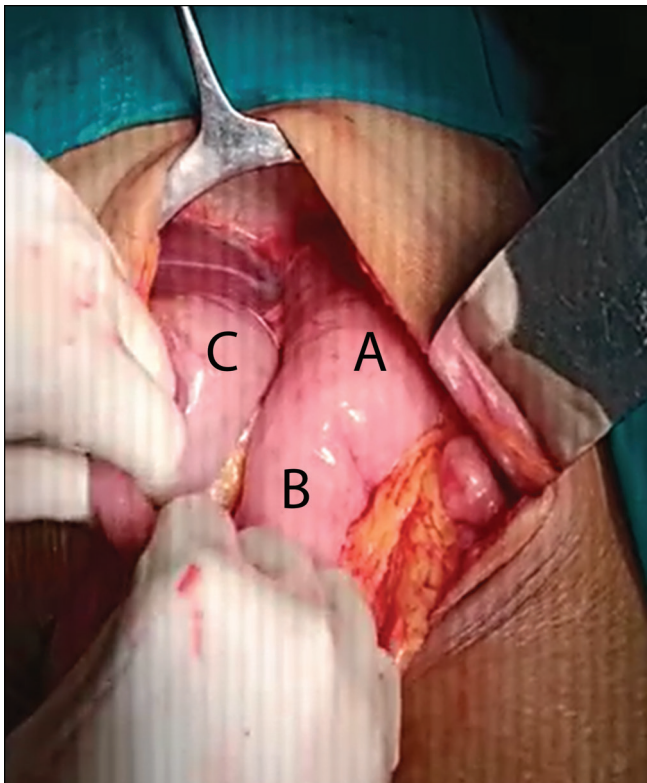


Figure 4: Contents of the paraesophageal hernia labeled as follows: (A) fundus of stomach, (B) body of stomach, and (C) antrum of stomach

benefit from a wait-and-watch approach, with emphasis on regular follow-up. According to a recent review, elective surgery should be offered to asymptomatic

patients and those experiencing minimal symptoms below the age of 75 years with large defects. This recommendation is possibly due to the high mortality rate associated with acute complications such as gastric volvulus.^[11]

Laparoscopic repair is the optimal surgical approach and the preferred treatment option due to its benefits, including shorter hospital stays, decreased post-operative pain, and reduced intra-operative or post-operative complications.^[12] Fundoplication is typically an essential step intraoperatively as it addresses underlying gastroesophageal reflux disease and lowers recurrence rates.^[13] An open laparotomy repair was selected for our patient due to concerns about possible volvulus, as reported in the preoperative imaging studies. Our patient also presented worrisome clinical features, including dysphagia to liquids and a tender epigastric mass upon palpation. The experience of the surgical team in managing paraesophageal hernias and associated complications through laparoscopy posed a limitation, leading to open repair being the preferred choice. Concerns about increased operative time leading to increased morbidity guided us to anatomically repair the defect without using a mesh.

Therefore, we conclude that the paraesophageal hernia exhibits varying presentations and mortality outcomes due to its possible complications. Patients derive the most benefit from an individualized approach that considers surgical fitness, symptom intensity, and complication risks. A thorough history, examination, and timely and appropriate investigations are crucial for accurate diagnosis and prevention of devastating sequelae. Both mesh and anatomical repair yield favorable outcomes, and the choice of surgical approach should be based on different factors such as patient demographics, clinical presentation, and available surgical expertise and facilities.

Author contributions

MV, VK, UM, and KRS contributed to drafting the text, sourcing, and editing clinical images, reviewing investigation results, creating original diagrams and algorithms, and critical revising the manuscript for important intellectual content. Final approval of the manuscript was given by VK and KRS.

Ethical policy and institutional review board statement

Not applicable.

Declaration of patient consent

The authors certify that they have obtained all appropriate patient consent forms. In the form the patient(s) has/have given his/her/their consent for his/her/their images and other clinical information to be reported in

the journal. The patients understand that their names and initials will not be published and due efforts will be made to conceal their identity, but anonymity cannot be guaranteed.

Data availability statement

Data sharing not applicable to this article as no datasets were generated and/or analyzed during the current study.

Financial support and sponsorship

Nil.

Conflicts of interest

There are no conflicts of interest.

Acknowledgements

Not applicable.

References

- Mazer L, Telem DA. Paraesophageal hernia. *Adv Surg* 2021;55:109-22.
- Landreneau RJ, Del Pino M, Santos R. Management of paraesophageal hernias. *Surg Clin North Am* 2005;85:411-32.
- Takeuchi N, Nomura Y. Paraesophageal hernia with incarceration of the gastric antrum and duodenal bulb: A case report. *BMC Res Notes* 2013;6:451.
- Dellaportas D, Papaconstantinou I, Nastos C, Karamanolis G, Theodosopoulos T. Large paraesophageal hiatus hernia: Is surgery mandatory? *Chirurgia (Bucur)* 2018;113:765-71.
- Mugino M, Little SC, Van der Wall H, Falk GL. High incidence of dyspnoea and pulmonary aspiration in giant hiatus hernia: A previously unrecognised cause of dyspnoea. *Ann R Coll Surg Engl* 2022;104:530-7.
- Oude Nijhuis RAB, van der Hoek M, Schuitenmaker JM, Schijven MP, Draaisma WA, Smout AJPM, *et al.* The natural course of giant paraesophageal hernia and long-term outcomes following conservative management. *United Eur Gastroenterol J* 2020;8:1163-73.
- Eero IS, Jarmo AS, Jari VR, Rantanen TK. Fatal complications of adult paraesophageal hernia: A population-based study. *J Thorac Cardiovasc Surg* 2009;137:419-24.
- Cardile AP, Heppner DS. Gastric volvulus, Borchardt's triad, and endoscopy: A rare twist. *Hawaii Med J* 2011;70:80-2.
- Haurani C, Carlin AM, Hammoud ZT, Velanovich V. Prevalence and resolution of anemia with paraesophageal hernia repair. *J Gastrointest Surg* 2012;16:1817-20.
- Lebenthal A, Waterford SD, Fisichella PM. Treatment and controversies in paraesophageal hernia repair. *Front Surg* 2015;2:13.
- Collet D, Luc G, Chiche L. Management of large para-esophageal hiatal hernias. *J Visc Surg* 2013;150:395-402.
- Zehetner J, Demeester SR, Ayazi S, Kilday P, Augustin F, Hagen JA, *et al.* Laparoscopic versus open repair of paraesophageal hernia: The second decade. *J Am Coll Surg* 2011;212:813-20.
- Klinginsmith M, Jolley J, Lomelin D, Krause C, Heiden J, Oleynikov D. Paraesophageal hernia repair in the emergency setting: Is laparoscopy with the addition of a fundoplication the new gold standard? *Surg Endosc* 2016;30:1790-5.