

Robot-assisted radical cystectomy for bladder cancer: single-center experience

Valentin Pavlov, Marat Urmantsev*, Ruslan Safiullin, Anton Denejko, Rita Gilmanova, Ruslan Abdrakhimov

Abstract

Objective: Radical cystectomy remains the most effective treatment for patients with localized, invasive bladder cancer and recurrent noninvasive disease. Recently some surgeons have begun to describe outcomes associated with less invasive surgical approaches to this disease, such as laparoscopic or robotic assisted techniques. We report our maturing experience with 100 consecutive cases of robotic assisted laparoscopic radical cystectomy regarding perioperative results, pathological outcomes, and surgical complications. **Methods:** A total of 100 consecutive patients (73 male and 27 female) underwent robotic radical cystectomy with intracorporeal urinary diversion at our institution from February 2018 to February 2021 for clinically localized bladder cancer. Outcome measures evaluated included operative variables, hospital recovery, pathological outcomes, and complication rate. **Results:** The mean age of this cohort was 60.4 years (range 38 to 82). Ninety-five patients underwent ileal conduit diversion, 5 received a neobladder). The mean operating room time for all patients was 184 min (min time was 160 min) and mean surgical blood loss was 286 ml. On surgical pathology, 2% of the cases were pT1, 35% were pT2, 51+12% were pT3/ T4 disease and 17% were node positive. The mean number of lymph nodes removed was 16 (range 10 to 40). In no case was there a positive surgical margin. The mean days to flatus were 2.6, bowel movement 2.8 and discharge home 8.2. There were 21 postoperative complications in 20 patients with 4% having a major complication (Clavien grade 3 or higher) and 15% being readmitted within 30 days after surgery. At a mean follow-up of 12 months 3 patients had disease recurrence and died 4 of disease. **Conclusions:** We report a relatively large cohort and maturing experience with robotic radical cystectomy for the treatment of bladder cancer, providing acceptable surgical and pathological outcomes. These results support continued efforts to refine the surgical management of muscle-invasive bladder cancer.

Bashkir State Medical University, Ufa 450074, Russia

*Corresponding author Marat Urmantsev, E-mail: urmantsev85@mail.ru

Received 16 January 2021, accepted 6 May 2021

1 Introduction

More than 500 000 new cases of bladder cancer are diagnosed each year in both sexes and all ages according to the worldwide statistics. The prevalence of this type of tumor is 3% of all malignancies in the global population^[1]. Radical cystectomy is a generally recognized standard of surgical care for patients in the world medical community, although this manipulation is associated with significant perioperative complications, longer hospital stays^[2] and increased mortality^[3]. In order to reduce the number of surgical complications after an open cystectomy, minimally invasive manipulation techniques have been developed^[4]. Robot-assisted radical cystectomy (RARC) show less surgical complications, as proven in a number of major studies^[5-8]. Moreover, RARC appears to be a more promising

method than a laparoscopic one, with a number of technical and functional advantages^[9]. Recently, there has been an increasing interest in RARC from the urological community, which has led to an increase in the frequency of using RARC as the selection for treatment of bladder cancer^[10-11].

2 Patients and Methods

We performed RARC for 100 patients by using a four-arm daVinci SI robotic system (Intuitive Surgical, CA, USA) between February 2018 and February 2021. Demographics, operative data, postoperative outcomes, and complications were recorded for each patient. The patient data are presented in Table 1. Robotic surgery was performed in the Clinic of Bashkir State Medical University by one experienced surgeon. The RARC was

begun with intracorporeal diversions in all cases. We performed extended pelvic lymph node dissection (ePLND) along with cystectomy for all patients. The lymph node was dissected at the level of extended template in all patients by removing the obturator, external iliac, common iliac, and presacral lymph nodes. In ileal conduit, a segment of the ileum of 20 cm was isolated and used for urinary diversion. The distal ends of both ureters were anastomosed to the ileum by the Wallace I or II technique. Ileal construction was performed according to the Studer reservoir for

orthotopic neobladder. Our RARC procedure is described in detail below. Postoperative early (0-30 days) and late (31-90 days) complications were evaluated using the modified Clavien-Dindo system. Minor complications were placed in Clavien category 1-2 and major complications in category 3-5 (Table 1).

Preoperational clinical stages included: 4 (4%) patients at cT1, 38 (38%) patients at cT2, 49 (49%) patients at pT3 and 9 (9%) patients at cT4 (Table 2).

Table 1 Patient characteristics

Variable	RARC (n = 100)
Age, year, mean	60,4 (38-82)
BMI, kg/m ² , mean	29.5 (3.9)
Male, n (%)	83 (83)
ASA grade, n (%)	
ASA1	10 (10)
ASA2	58 (58)
ASA3	32 (32)

ASA = American Society of Anesthesiologists; BMI = body mass index

Table 2 Oncological characteristics

RARC	100 patients
Clinical Stage	
cT1	4
cT2	38
cT3	49
cT4	9
Tumor grade (biopsy)	
G1	4
G2	44
G3	52

3 Surgery technique

First 10-mm port for camera was placed in the middle of umbilicus and processus xiphoideus. After pneumoperitoneum - three 8-mm robotic ports: two were placed on the right side and one on the left. One of the right ports was at the same area where ileostomy was to be done. Two assistance ports were placed at the end laterally (8 mm) and medially (10 mm) on the left side, and an 8-mm port was placed for robotic arm between the assistance ports (Fig.1) The patient was moved to a 30° Trendelenburg position, and docking of the robot arms was performed. The surgeon used two right robotic arms and one left. This position improves working in two anatomic area (for cystectomy and for ileal reconstruction).

We commenced dissection from the Douglas pouch, posterior of the bladder, seminal vesicles, and ducts, prostate to urethra (Fig.2) Lymphadenectomy was an integral part of radical cystectomy. After posterior dissection we opened right common ileac vessels with lymph node dissection from bifurcation to bladder pedicles to endopelvic fascia. During this procedure we were clipping a. vesicles inferior and a. umbilicalis. The right ureter was clipped close to bladder (Fig.3). The rectum and sigmoid colon were moved to the right, and an analogical dissection was made from bifurcation on the left side. At the end of lymphadenectomy, left ureter was being passed behind mesentery to the left side. Lymphadenectomy was performed to cover the external, internal, and common iliac, obturator, and presacral LNs (bilateral

ePLND) (Fig.4) Anterior dissection was started from urachus by the plica umbilicalis medialis to the front side of the bladder and prostate until urethra. Urethra cut and organ complex were moved to endobag. Two ureters on the left side were anastomosed to the ureters by the Wallace technique using 4/0

vicryl (Fig.5) The ileal pouch was formed using the 20 cm ileal segment, proximally 20 cm from the ileocecal valve, and the remaining intestinal segment was anastomosed with a stapler. Mono J ureter stents were placed in both ureters, and the ileal pouch was anastomosed (Fig.6)

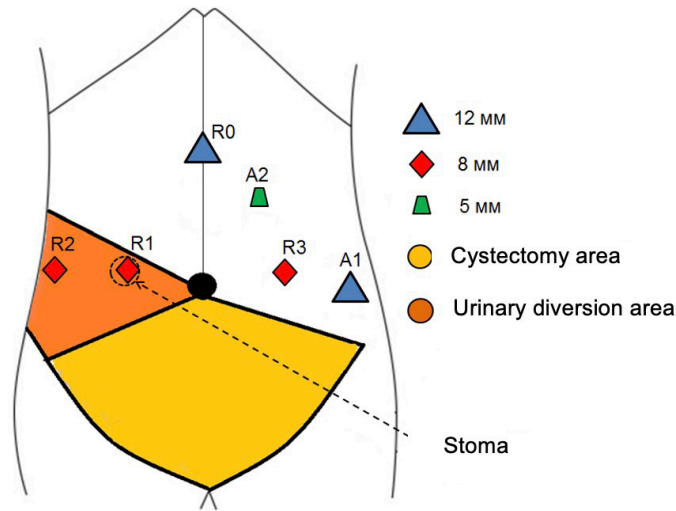


Fig. 1 Port placement for RARC

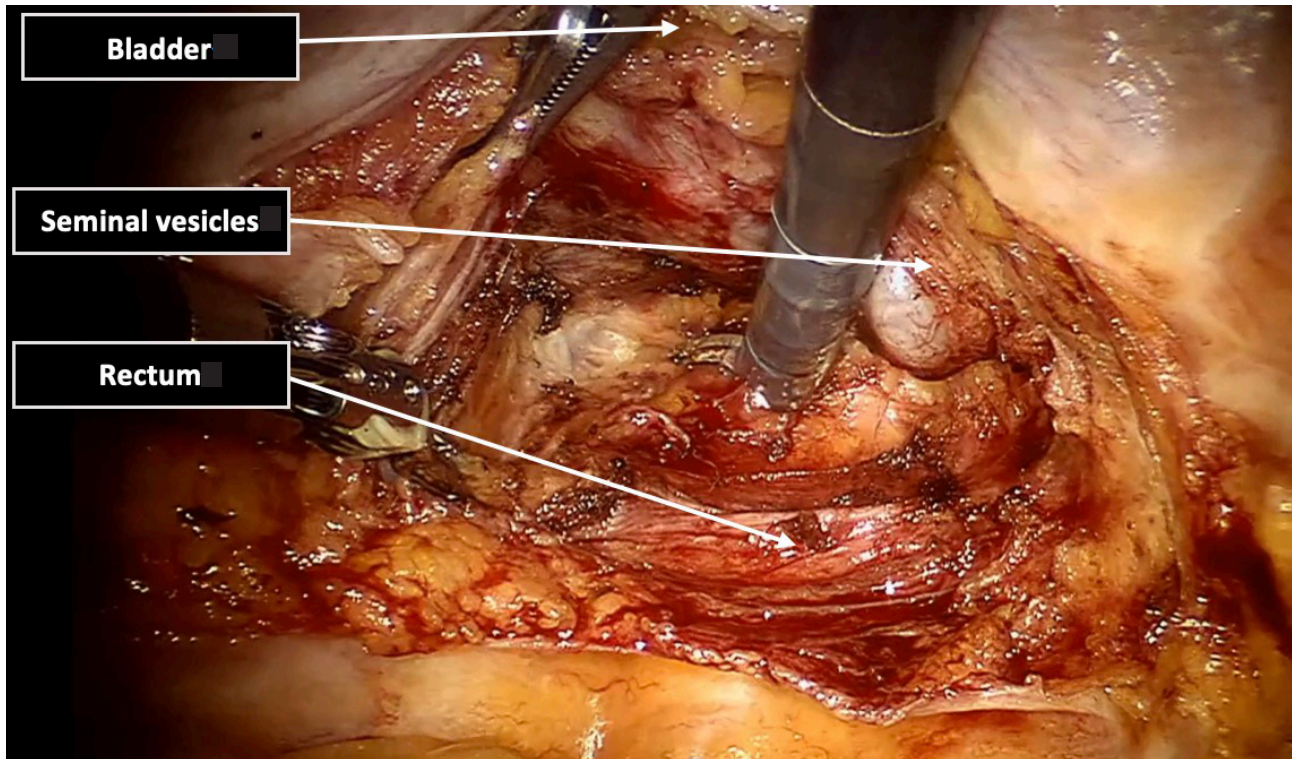


Fig. 2 Posterior dissection (from the Douglas pouch, posterior of the bladder, seminal vesicles, and ducts, prostate to urethra)

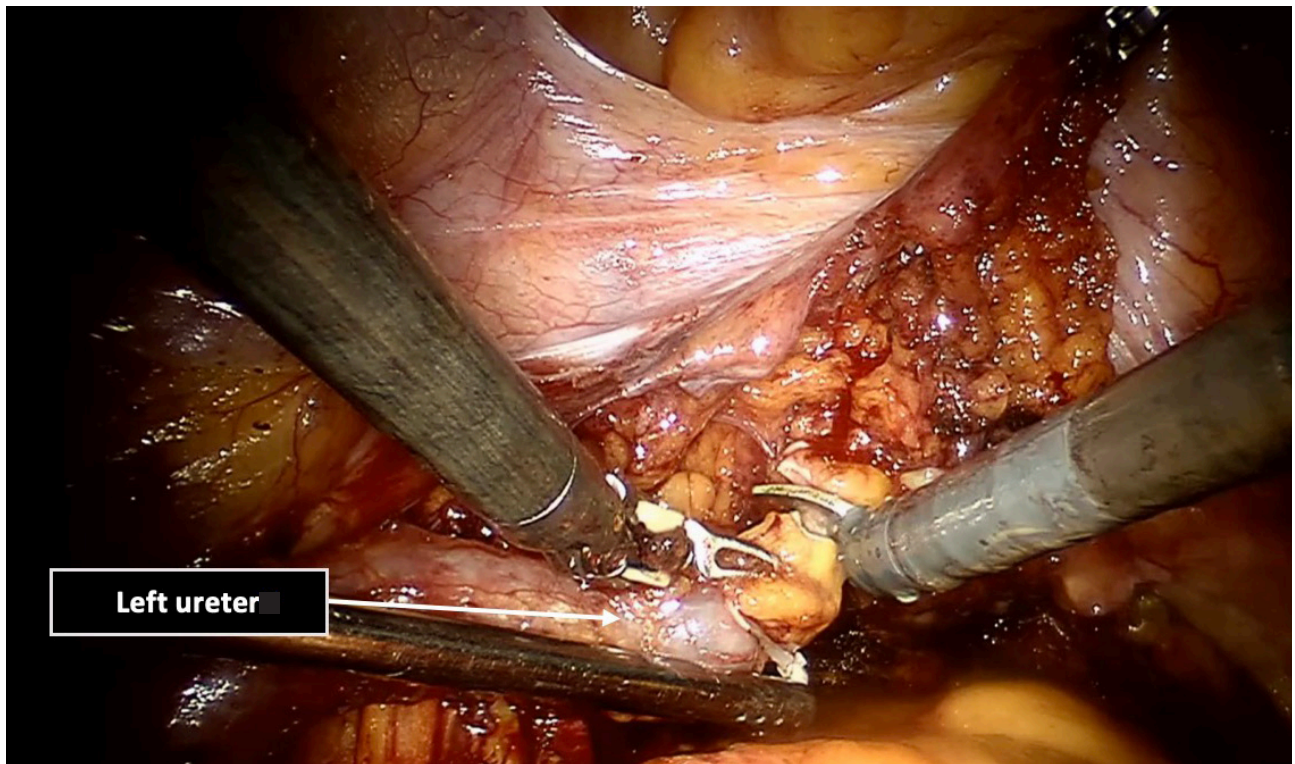


Fig. 3 Left ureter clipping close to bladder

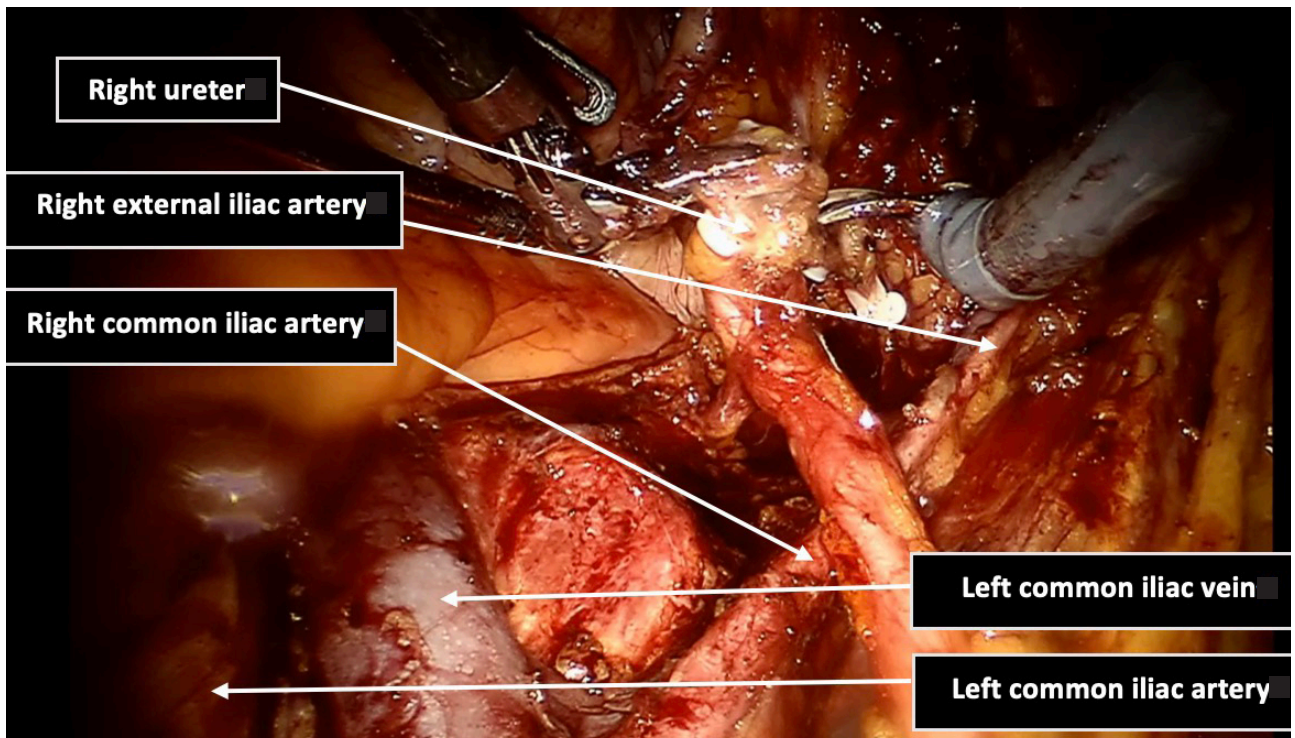


Fig. 4 Right ureter clipped. ePLND was performed (external, internal, and common iliac; obturator, and presacral)

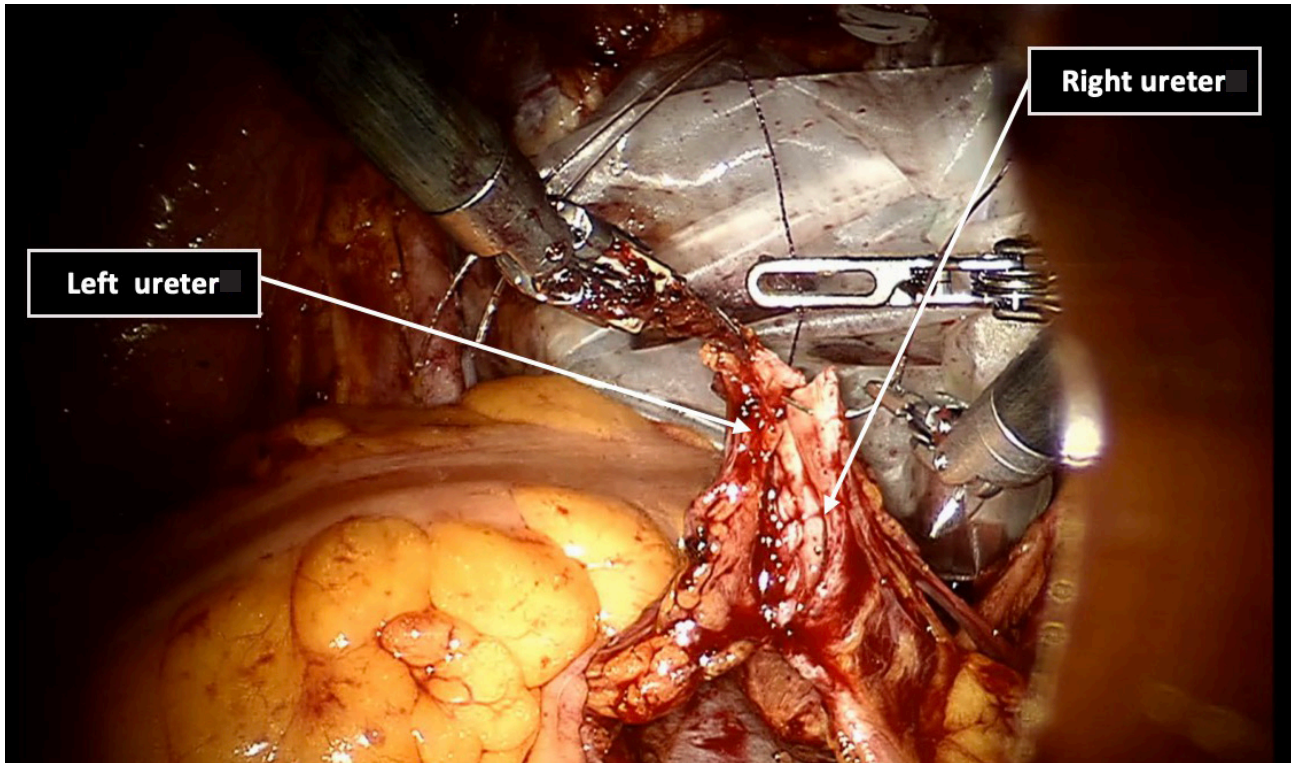


Fig. 5 Anastomosis between ureters (Wallace I technique)

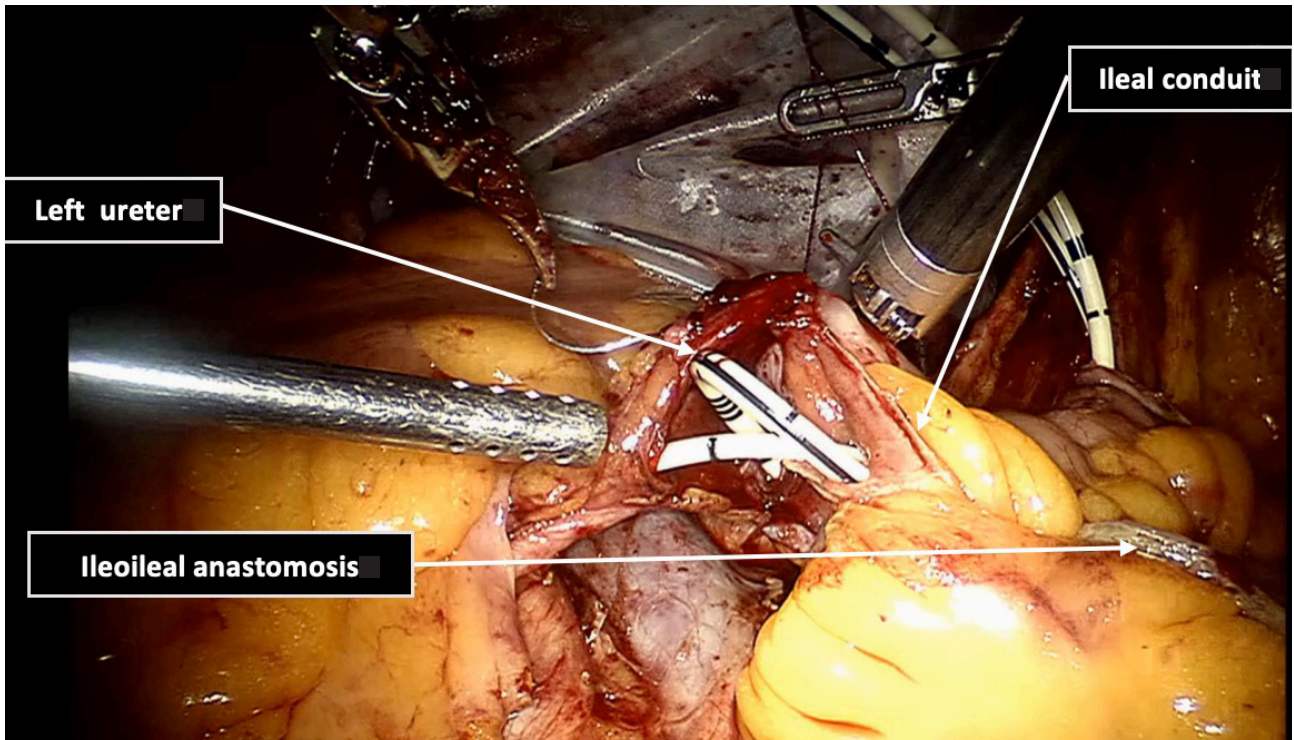


Fig. 6 Anastomosis between ileal conduit and ureters (inside ureters J stents)

4 Results

A total of 100 patients (73 males, 27 females) who underwent RARC and ePLND were included in the study, of whom 95 (95%) received intracorporeal ileal conduit, 5 (5%) received intracorporeal orthotopic neobladder. The mean age of the patients was 60.4 ± 9.09 years. The mean operation time was 184 ± 86 min, and the mean estimated blood loss was 286 ± 91 mL. The mean lodge drain and hospitalization time were 7.4 ± 3.4 and 8.2 ± 5.1 days, respectively. Demographics and operative parameters are shown in Table 3.

Postoperative pathologic stages were pT1 ($n = 2$), pT2 ($n = 35$),

pT3 ($n = 51$), and pT4 ($n = 12$). In pT4 patients, invasions were seen in the prostate ($n = 5$), vagina, uterus ($n = 5$), and seminal vesicle (2). Three patients had concomitant prostate cancer (Gleason score 3+3). In our Clinic all patients who had cT3-4 underwent neoadjuvant chemotherapy prior to cystectomy. Adjuvant chemotherapy was offered to patients who had pT3-4 and/or LN metastasis. The distribution of pathology outcomes is presented in Table 4.

The mean follow-up period was 12.1 ± 3.2 months, and 4 patients died during follow-up, of whom 2 died due to bladder cancer and 2 due to cardiac (1) and pulmonary (1) diseases. Three patients had local or distant metastasis, and they all received chemotherapy for metastasis.

Table 3 Patient's characteristics

Variable	Number of patients ($n = 100$)
Sex Male/Female	73/27
Urinary diversion type, n (%)	
Ileal conduit (Bricker)	15 (26.34%)
Neobladder (Studer)	17 (29.8%)
Mean operative time, min (\pm SD)	184 ± 86
Mean estimated blood loss, mL (\pm SD)	286 ± 91
Mean hospitalization time, days (\pm SD)	8.2 ± 5.1
Mean removal drain time, days (\pm SD)	7.4 ± 3.4
Mean follow-up, months (\pm SD)	12.1 ± 3.2

Table 4 Pathological outcomes

Stages	RARC 100
Clinical stage	
pT1	2
pT2	35
pT3	51
pT4	12
Pathological stage	
pG1	1
pG2	54
pG3	45
Lymph node yield	
N0	87
N1	12
N2	5

Table 5 30 day complications

Complications	n	RARC 100
Anemia	5	Blood transfusion
Lymphocele	2	Observation
Ureteroileal anastomosis leak	4	Nephrostomy
Wound infection	-	
Ileoileal anastomosis leak	2	Laparotomy. Ileostomy. Ureterocutaneostomy
Urinary infection	3	parenteral antibiotic treatment
Ileus	4	parenteral serotonin receptor agonists
Deep vein thrombosis	1	Anticoagulant treatment

Table 6 90 day complications

Complications	n	Management
Hydronephrosis/Ureteroileal anastomosis stricture	2	Nephrostomy
Urinary infection	5	Parenteral antibiotic treatment

5 Discussion

The current state of minimally invasive surgery in urology is characterized by high relevance and perspective. This advance is well appreciated after the long stagnation of traditional methods of surgical treatment of urinary tract pathologies. In the late 1990s and early 2000s, there was a sharp jump in surgical assistance for the treatment of urological diseases because of the advent of the breakthrough method of robot-assisted intervention. This high-tech method has demonstrated its superiority and high standard to all areas of surgical practice. However, more solid evidence for validating its efficacy is needed with well-designed large-scale randomized clinical trials. The results documented by Feng *et al.*^[12], as by many other teams on the same subject, show the superiority of RARC before open surgery in terms of surgical criteria, except for the time of surgery. Fonseca *et al.*^[13] reported that RARC requires a longer operating time but shorter hospitalization time compared to other technologies. Also, many researchers have noticed the comparability of early cancer outcomes following robotic right colectomy (RRC) and conventional laparoscopic right colectomy (LRC) and the advantages of these technologies over the open radical cystectomy^[14-15].

In the current study, the mean operation time was 184 ± 86 min and the blood loss was 286 ± 91 mL. International Robotic Cystectomy Consortium^[16] reported operation time of 371 min and

blood loss of 300 mL, whereas Khan *et al.*^[18] reported 389 min and 585 mL, respectively. Our study showed shorter operation time than the published studies. Porreca *et al.*^[17,19] reported that operation time and blood loss decreased depending on the experience at the learning curve: operation time decreased from 399 min to 373 min and blood loss from 425 mL to 250 mL compared with the first 24 cases and the last 34 cases. We observed the same correlation in our study.

Shorter lodge drain and hospitalization time and lower complication rates are important advantages of RARC over open radical cystectomy (ORC). Previous studies reported hospitalization time of 4-17.1 days^[20-21]. In the current study, the hospitalization time was 8.2 ± 5.1 days, and the duration of lodge drain was 7.4 ± 3.4 days, which are similar to the literature data. Nonetheless, implementation of the enhanced post-surgery recovery program in our center significantly shortened hospitalization time and lodge drain duration.

It has been addressed that low complication rate is an important advantage of RARC^[22]. Canda *et al.*^[23] reported a minor complication rate of 33.3% and a major complication rate of 14.81% within the period of 0-30 days, which were reduced to 14.81% and 11.11%, respectively, after a prolonged period of 30-90 days. Schumacher *et al.*^[24] reported 40% (17.78% minor,

22.22% major) complication rates in the early phase and 30% (13.33% minor, 17.77% major) complication rates in the late phase of their RARC series. International Robotic Cystectomy Consortium reported the overall complication and major complication rates of 50% and 11%, respectively, in their multicenter study^[16]. Our early-phase (0-30 days period) and late-phase (31-90 days period) complication rates were 18% and 7%, respectively. Collectively, the results we have obtained strengthen the position of RARC as the mainstay procedure for bladder cancer treatment.

Ethical approval and informed consent

This study was approved by the ethical committee of Bashkir State Medical University (No. 200n), and all participants signed informed consent form.

Conflicts of interests

All authors declare no competing financial interest.

References

- [1] International Agency for Research on Cancer. Global Cancer Observatory. <https://gco.iarc.fr/>. Accessed on October 12, 2020.
- [2] Shabsigh A, Korets R, Vora K C, *et al*. Defining early morbidity of radical cystectomy for patients with bladder cancer using a standardized reporting methodology. *Eur Urol*, 2009; 55(1): 164-174.
- [3] Lowrance W T, Rumohr J A, Chang S S, *et al*. Contemporary open radical cystectomy: analysis of perioperative outcomes. *J Urol*, 2008; 179(4): 1313-1318.
- [4] Ukimura O, Moizadeh A, Gill I S. Laparoscopic radical cystectomy and urinary diversion. *Curr Urol Rep*, 2005; 6(2): 118-121.
- [5] Bochner B H, Sjoberg D D, Laudone V P. Memorial sloan kettering cancer center bladder cancer surgical trials group. A randomized trial of robot-assisted laparoscopic radical cystectomy. *N Engl J Med*, 2014; 371(4): 389-390.
- [6] Khan M S, Gan C, Ahmed K, *et al*. A single-centre early phase randomised controlled three-arm trial of open, robotic, and laparoscopic radical cystectomy (CORAL). *Eur Urol*, 2016; 69(4): 613-621.
- [7] Novara G, Catto J W, Wilson T, *et al*. Systematic review and cumulative analysis of perioperative outcomes and complications after robot-assisted radical cystectomy. *Eur Urol*, 2015; 67(3): 376-401.
- [8] Guliev B G, Bolokotov R R. Robot-assisted and open radical cystectomy: comparative analysis of results. *Urology Herald*, 2020; 8(1): 59-68. (In Russ.)
- [9] Challacombe B J, Bochner B H, Dasgupta P, *et al*. The role of laparoscopic and robotic cystectomy in the management of muscle-invasive bladder cancer with special emphasis on cancer control and complications. *Eur Urol*, 2011; 60(4): 767-775.
- [10] Gill I, Cacciamani G E. The changing face of urologic oncologic surgery from 2000-2018 (63141 patients)-impact of robotics. *Eur Urol*, 2019; 18(1): e656-e657.
- [11] Mistretta F A, Luzzago S, Musi G, *et al*. Minimally invasive versus open radical cystectomy: long term oncologic outcomes compared. *Transl Androl Urol*, 2020; 9(3): 1006-1008.
- [12] Feng D, Li A, Hu X, *et al*. Comparative effectiveness of open, laparoscopic and robot-assisted radical cystectomy for bladder cancer: a systematic review and network meta-analysis. *Minerva Urol Nefrol*, 2020; 72(3): 251-264.
- [13] Fonseka T, Ahmed K, Froghi S, *et al*. Comparing robotic, laparoscopic and open cystectomy: a systematic review and meta-analysis. *Arch Ital Urol Androl*, 2015; 87(1): 41-48.
- [14] Khan M S, Omar K, Ahmed K, *et al*. Long-term Oncological Outcomes from an Early Phase Randomised Controlled Three-arm Trial of Open, Robotic, and Laparoscopic Radical Cystectomy (CORAL). *Eur Urol*, 2020; 77(1): 110-118.
- [15] Kim T H, Sung H H, Jeon H G, *et al*. Oncological outcomes in patients treated with radical cystectomy for bladder cancer: comparison between open, laparoscopic, and robot-assisted approaches. *J Endourol*, 2016; 30(7): 783-791.
- [16] Hussein A A, May P R, Jing Z, *et al*. Outcomes of intracorporeal urinary diversion after robot-assisted radical cystectomy: results from the International Robotic Cystectomy Consortium. *J Urol*, 2018; 199(5): 1302-1311.
- [17] Porreca A, Bianchi F M, Romagnoli D, *et al*. Robot-assisted radical cystectomy with totally intracorporeal urinary diversion: surgical and early functional outcomes through the learning curve in a single high-volume center. *J Robot Surg*, 2020, 14(1): 261-269.
- [18] Khan M S, Gan C, Ahmed K, *et al*. A single-centre early phase randomised controlled three-arm trial of open, robotic, and laparoscopic radical cystectomy (CORAL). *Eur Urol*, 2016; 69(4): 613-621.
- [19] Porreca A, Chessa F, Romagnoli D, *et al*. Robot assisted radical cystectomy with totally intracorporeal urinary diversion: initial, single-surgeon's experience after a modified modular training. *Minerva Urol Nefrol*, 2018; 70(2): 193-201.
- [20] Richards K A, Kader K, Pettus J A, *et al*. Does initial learning curve compromise outcomes for robot-assisted radical cystectomy? A critical evaluation of the first 60 cases while establishing a robotics program. *J Endourol*, 2011; 25(9): 1553-1558.
- [21] Sim A, Balbay M D, Todenhöfer T, *et al*. Robot-assisted radical cystectomy and intracorporeal urinary diversion—safe and reproducible? *Cent Eur J Urol*, 2015; 68(1): 18-23.
- [22] Kader A K, Richards K A, Krane L S, *et al*. Robot-assisted laparoscopic vs open radical cystectomy: comparison of complications and perioperative oncological outcomes in 200 patients. *BJU Int*, 2013; 112: e290-e294.
- [23] Canda A E, Atmaca A F, Altinova S, *et al*. Robot-assisted nerve-sparing radical cystectomy with bilateral extended pelvic lymph node dissection (PLND) and intracorporeal urinary diversion for bladder cancer: initial experience in 27 cases. *BJU Int*, 2012; 110(3): 434-444.
- [24] Schumacher M C, Jonsson M N, Hosseini A, *et al*. Surgery-related complications of robot-assisted radical cystectomy with intracorporeal urinary diversion. *Urology*, 2011; 77(4): 871-876.