

## RESEARCH ARTICLE

# A retrospective analysis of 350 cases of parotid gland tumors and the value of ultrasound in the diagnosis of benign and malignant parotid gland tumors

Wen Gao | Lifei Feng | Zishi Huang | Duoxuan Chen | Wei Guo | Gaofei Yin | Yang Zhang | Zhigang Huang

Department of Otolaryngology Head and Neck Surgery, Beijing Tongren Hospital, Capital Medical University, Key Laboratory of Otolaryngology Head and Neck Surgery (Capital Medical University), Ministry of Education, Beijing, China

## Correspondence

Zhigang Huang and Yang Zhang, Department of Otolaryngology Head and Neck Surgery, Beijing Tongren Hospital, Capital Medical University, 1, Dongjiaominxiang Street, Dongcheng District, Beijing 100730, China. Email: [enthuangzhigang@sohu.com](mailto:enthuangzhigang@sohu.com) and [zhangyangent@163.com](mailto:zhangyangent@163.com)

## Funding information

Beijing Municipal Science and Technology Commission, Administrative Commission of Zhongguancun Science Park, Grant/Award Number: Z221100007422045; National Natural Science Foundation of China, Grant/Award Number: 82072997

## Abstract

**Objective:** To retrospective analysis of the epidemiological and clinical characteristics of parotid gland tumors, and to explore the value of ultrasound in the differentiation of benign and malignant parotid gland tumors.

**Methods:** The clinical data of 350 patients with parotid gland tumors in our hospital from 2002 to 2022 were retrospectively analyzed. These patients were examined by ultrasound. The postoperative pathological test results were used as the “gold standard” to verify and analyze the value of color Doppler ultrasound in the differential diagnosis of benign and malignant parotid tumors (PT).

**Results:** The male-to-female ratio of 350 patients with parotid gland tumors was 1.16:1. The age of patients ranged from 12 to 87 years old. Patients aged 40–65 years accounted for 54.6%, which was the most common age of parotid gland tumors. Among 350 cases, 259 were benign and 91 were malignant. The top three benign PTs were pleomorphic adenoma, Warthin tumor, and basal cell adenoma. The top three malignant tumors were mucoepidermoid carcinoma, acinar cell carcinoma, and adenoid cystic carcinoma. The specificity, sensitivity, accuracy, positive predictive value, and negative predictive value of ultrasonography in the diagnosis of benign and malignant parotid masses were 96.53%, 69.23%, 89.43%, 87.50%, and 87.72%, respectively.

**Conclusion:** The pathological types of parotid gland tumors are complex and diverse. Ultrasonography has high accuracy in the diagnosis of PT, which can provide important evidence for the differentiation of benign and malignant PT, and then assist in the clinical selection of individualized surgical programs.

## KEYWORDS

benign and malignant diagnosis, parotid gland tumor, retrospective analysis, ultrasound

Wen Gao and Lifei Feng contributed equally to this work.

This is an open access article under the terms of the Creative Commons Attribution License, which permits use, distribution and reproduction in any medium, provided the original work is properly cited.

© 2024 The Authors. *Eye & ENT Research* published by John Wiley & Sons Australia, Ltd on behalf of Higher Education Press.

## INTRODUCTION

Salivary gland tumors are relatively uncommon, with parotid gland tumors being the most prevalent, accounting for 70%–80% of salivary gland tumors, 2%–3% of head and neck tumors, and 0.6% of all tumors [1]. The World Health Organization (WHO) 2017 classification recognizes a wide range of histological types for salivary gland tumors, encompassing 20 malignant tumors and 11 benign tumors. Pleomorphic adenoma is the most frequently occurring benign parotid gland tumor, followed by Warthin tumor. On the other hand, mucoepidermoid carcinoma is the most prevalent malignant tumor of the parotid gland, followed by adenoid cystic carcinoma [2]. The etiology and pathogenesis of these tumors remain unknown. Parotid tumors (PT) typically manifest as masses under the earlobe, in the preauricular region, or behind or within the lower part of the parotid gland. Clinically, facial paralysis is rarely observed in benign parotid gland tumors, even when they are large. In contrast, malignant parotid gland tumors tend to exhibit rapid growth and invasiveness, potentially affecting the facial nerve and causing abnormal nerve function, such as varying degrees of facial paralysis, pain, and numbness of the tongue, thereby significantly impacting the patient's quality of life. Nonetheless, the clinical manifestations of certain parotid gland malignancies resemble those of benign tumors, posing challenges for preoperative diagnosis [3]. Currently, surgical resection is the primary treatment for PT, and the choice of surgical approach and extent largely depends on the benign or malignant nature of the tumors [4]. Early identification of the tumor's nature and the implementation of individualized treatment programs are critical to improving the patient's quality of life. Color Doppler ultrasound is typically the preferred diagnostic method for parotid gland tumors [5]. Therefore, this study aims to review and analyze the clinical data from parotid gland tumor patients admitted in recent years, to summarize the incidence and clinical characteristics of the patients, and to discuss the value of color Doppler ultrasound in the identification of benign and malignant PT. The findings of this study can serve as a valuable reference for clinical diagnosis and treatment.

## CASES AND METHODS

### Source of case data

The data of patients with parotid gland tumors who were admitted to Beijing Tongren Hospital from 9 January 2002 to 24 February 2022 were collected.

### Inclusion criteria

All patients included in the study underwent ultrasound examinations at our hospital. Surgical resection was performed under general anesthesia with tracheal intubation for all cases. The inclusion criteria required patients to be older than 3 years old, admitted for initial surgical treatment, and had postoperative pathology confirming the

presence of benign or malignant parotid gland tumors. Cases of focal malignancy were classified as malignant tumors.

### Exclusion criteria

Patients with incomplete clinicopathological data, unknown surgical records, and uncertain pathological results were excluded.

### Research methods

The study retrospectively analyzed clinical data from 350 patients diagnosed with parotid gland tumors, and the disease characteristics, age, gender, tumor site, surgical methods, and pathological results were summarized for statistical analysis. The diagnostic performance of ultrasound in differentiating between benign and malignant parotid masses was assessed by comparing the ultrasound results with postoperative pathological examination results, which served as the "gold standard" for pathological classification based on the 2017 WHO histological classification of salivary gland tumors. The statistical measures of specificity, sensitivity, and accuracy were employed to evaluate the diagnostic efficacy.

The following statistical methods were utilized for specificity, sensitivity, and accuracy calculations:

Ultrasound	Postoperative pathology		Total
	Malignant	Benign	
Malignant	a	b	a + b
Benign	c	d	c + d
Total	a + c	b + d	n

$$\text{Sensitivity} = a / (a + c) \times 100\%;$$

$$\text{Specificity} = d / (b + d) \times 100\%;$$

$$\text{Accuracy} = (a + d) / n \times 100\%;$$

### Statistical analysis

Data analysis was conducted using SPSS 23.0 statistical software. Count data were expressed as percentages (%), and comparisons were performed using the chi-square test. A *p*-value less than 0.05 was considered statistically significant.

## RESULTS

### Pathogenetic characteristics

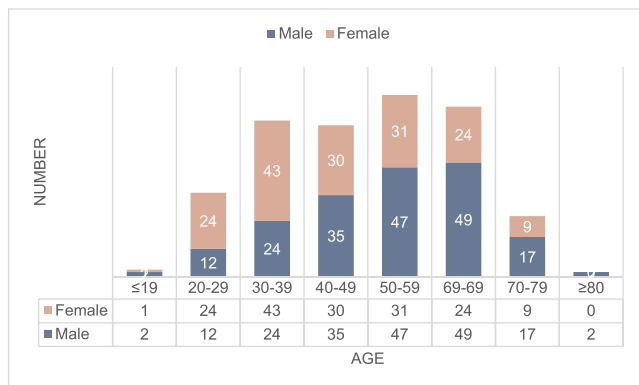
#### Gender and age distribution at onset

Among the 350 collected patients with parotid gland tumors, 188 were male and 162 were female, resulting in a male to female ratio of

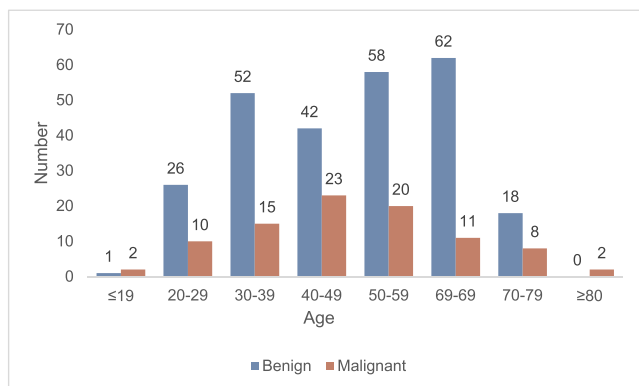
1.16:1. The age of the patients ranged from 12 to 87 years old, with a median age of 50 years and a mean age of 48.9 years. The highest incidence of parotid gland tumors occurred in the age group of 30–69 years, accounting for 80.9% of cases. Within this age group, the peak incidence was observed among individuals aged from 50 to 59 years old, accounting for 22.3% of the cases. The number of male cases increased significantly from 40 to 49 years old, while female cases showed a significant increase from 30 to 39 years old (Figure 1).

### Age distribution of benign and malignant parotid tumors

Among the 350 cases of parotid gland tumors, 259 cases were benign and 91 cases were malignant. For patients with benign PT, the average age was 49.3 years old and the highest incidence was observed in the age range of 30–69 years old (214 cases, accounting for 82.6%), with a peak incidence between 50 and 69 years old. Among patients with parotid gland malignancies, the peak onset occurred between the ages of 40 and 59 years, with an average age of 51.7 years (Figure 2).



**FIGURE 1** Relationship between gender and age of 350 patients with parotid gland tumor.



**FIGURE 2** The relationship between benign and malignant and age in 350 patients with parotid gland tumor.

### Pathogenetic side (tumorous position)

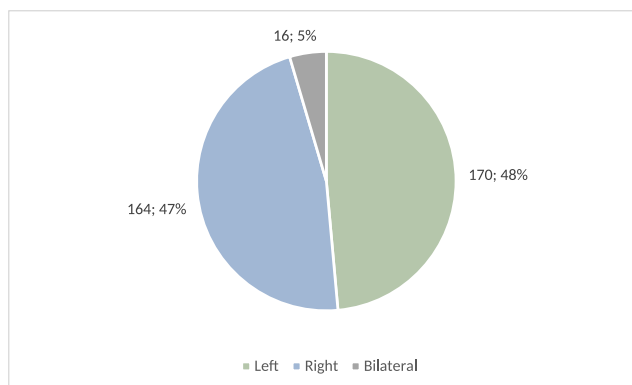
Among the 350 collected patients with parotid gland tumors, 170 cases (48.6%) were located on the left side, 164 cases (46.8%) on the right side, and 16 cases (4.6%) exhibited bilateral tumors with the same pathological type affecting both sides (Figure 3).

### Disease progression

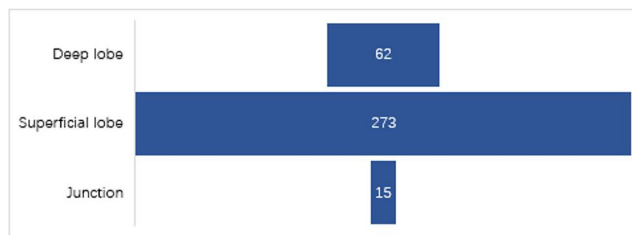
Among the 350 patients with parotid gland tumors, the duration from tumor discovery to the first visit ranged from 2 days to 50 years. A total of 107 cases (30.6%) had a disease duration of less than 3 months and 95 cases (27.1%) had a disease duration exceeding 3 years.

### Auxiliary examination

Color Doppler ultrasound was the primary choice for preoperative examination, followed by CT and MRI to further assess the tumor's extent and to determine the appropriate surgical method. Based on clinical examination and related imaging findings, the preoperative examination reports showed that 273 cases (78.0%) had tumors originating from the superficial lobe of the parotid gland, 62 cases (17.7%) had tumors originating from the deep lobe of the parotid gland, and 15 cases (4.3%) had tumors originating at the junction between the deep and superficial lobes (Figure 4).



**FIGURE 3** Sites of parotid gland tumor in 350 cases.



**FIGURE 4** Constituent ratio of depth in 350 patients with parotid gland tumors.

## Surgical methods

All 350 patients with parotid gland tumors underwent surgical treatment. Among the 259 cases of benign parotid gland tumors, 255 cases underwent partial parotidectomy with facial nerve preservation, while 4 cases underwent total parotidectomy with facial nerve preservation. Among the 91 cases of malignant parotid gland tumors, 62 cases underwent total parotidectomy with facial nerve preservation, and 29 cases underwent total parotidectomy with facial nerve preservation and ipsilateral selective neck deep lymph node dissection due to malignant tumor invasion of the cervical lymph nodes.

## Histopathological types

Among the 350 cases of parotid gland tumors, 259 cases were benign and 91 cases were malignant (Table 1). The top three benign PTs were pleomorphic adenoma (132 cases, 51.0%), Warthin tumor (87 cases, 33.5%), and basal cell adenoma (30 cases, 11.6%). The top three malignant PTs were mucoepidermoid carcinoma (32 cases,

35.2%), acinar cell carcinoma (13 cases, 14.3%), and adenoid cystic carcinoma (10 cases, 10.9%). In terms of gender distribution within the benign tumors, both pleomorphic adenoma and basal cell adenoma were found to be more prevalent in females, with male-to-female ratios of 1:1.75 and 1:3.28, respectively. Conversely, Warthin tumor exhibited a higher incidence in males, with a male-to-female ratio of 9.9:1. Among the malignant tumors, mucoepidermoid carcinoma and adenoid cystic carcinoma were more common in females, with male-to-female ratios of 0.88:1 and 0.7:1, respectively. It is important to note that the number of cases for other histopathological types was insufficient to draw meaningful comparisons or establish reference significance.

## Comparison of the predicted results of color ultrasound examination and postoperative pathological results

Based on postoperative pathological results considered the "gold standard", a total of 259 cases of benign tumors and 91 cases of

**TABLE 1** Constituent ratio and gender distribution of 350 cases of parotid gland tumors.

Histologic types	Gender		Total	Percentage (%)
	Male	Female		
Benign	139	120	259	
Pleomorphic adenoma	48	84	132	51.0
Whartin's tumor	79	8	87	33.5
Basal cell adenoma	7	23	30	11.6
Oncocytoma	0	2	2	0.8
Myoepithelioma	1	0	1	0.4
Sebaceous adenoma	1	0	1	0.4
Others	3	3	6	2.3
Malignant	49	42	91	
Mucoepidermoid carcinoma	15	17	32	35.2
Acinic cell carcinoma	3	10	13	14.3
Adenoid cystic carcinoma	5	5	10	10.9
Intraductal carcinoma	5	1	6	6.6
Sebaceous carcinoma	4	1	5	5.5
Adenocarcinoma	4	0	4	4.4
Pleomorphic adenocarcinoma	3	1	4	4.4
Squamous cell carcinoma	2	2	4	4.4
Secretory carcinoma	3	1	4	4.4
Myoepithelial carcinoma	1	1	2	2.2
Carcinosarcoma	1	0	1	1.1
Lymphoma	3	2	5	5.5
Others	0	1	1	1.1
Total [n (%)]	188 (53.7)	162 (46.3)	350	

malignant tumors were pathologically diagnosed among the 350 patients. Ultrasound diagnosis accurately identified 250 out of 259 cases of benign PT (sensitivity: 96.53%) and 63 out of 91 cases of malignant PT (sensitivity: 69.23%). The specificity, sensitivity, and accuracy were calculated according to the method described in Section 1.4 (Research Methods). The specificity, sensitivity, accuracy, and positive and negative predictive value for ultrasound diagnosis of benign and malignant parotid masses were 96.53% (250/259), 69.23% (63/91), 89.43% (313/350), 87.50% (63/72), and 87.72% (250/285), respectively (Table 2).

### Ultrasound features of parotid gland tumors

This study compared and analyzed 259 benign tumors and 91 malignant tumors based on characteristics such as boundary, shape, echo distribution, and blood flow. The observed differences were found to be statistically significant ( $p < 0.05$ ). However, there was no significant difference in the internal echo (whether the tumor was hypoechoic or not) between the two groups ( $p > 0.05$ ), as outlined in Table 3. Notably, malignant tumors are characterized by unclear

**TABLE 2** Comparison of ultrasound prediction with postoperative pathology ( $n$ ).

Ultrasound	Postoperative pathology		Total
	Malignant	Benign	
Malignant	63	9	72
Benign	28	250	285
Total	91	259	350

**TABLE 3** Comparison of ultrasound features between benign and malignant parotid tumors.

Ultrasound features	Benign or malignant		$\chi^2$	$p$
	Benign ( $n = 259$ )	Malignant ( $n = 91$ )		
Boundary			58.10	0.000
Clear	237	51		
Unclear	22	40		
Shape			25.11	0.000
Regular	164	30		
Irregular	95	61		
Internal echo			0.30	0.586
Hypoecho	180	66		
Non hypoechoic	79	25		
Homogeneous echo			32.71	0.000
Yes	150	21		
No	109	70		
Apparent blood flow			5.709	0.017
Yes	116	54		
No	143	37		

boundaries, irregular shapes, uneven internal echoes, and prominent blood flow signals under ultrasound examination ( $p < 0.05$ ), distinguishing them from benign tumors.

### DISCUSSION

The parotid gland, which is the largest among the three salivary glands, serves as a primary site for salivary gland tumors. It consists of the parenchyma and stroma. Approximately 64%–80% of all primary salivary gland tumors involve the parotid gland, with the majority originating in the superficial lobe [6]. Parotid gland neoplasms can occur in both men and women, spanning various age groups. Yu Guangyan et al. [7], a Chinese scholar, collected a large number of clinical data and found that the male-to-female morbidity ratio was about 1.1:1, and the age of onset was concentrated between 20 and 70 years old. Our research yielded similar results. In our study, the male-to-female ratio was 1.16:1, and the onset age of parotid gland tumors was concentrated between the ages of 30 and 69, accounting for 80.9%. According to relevant literature, benign tumors tend to manifest at an earlier age compared to malignant tumors [8–10]. Multiple studies indicate that the mean age of malignant tumors (about 55 years) is higher than that of benign tumors (about 45 years) [8,9,11]. In the study conducted by Senol Comoglu et al. [12], the mean age of PT was reported as 47.7 years, with 47.0 years for benign PT and 50.7 years for malignant PT. In our retrospective analysis, we observed a mean age of onset of 49.3 years in patients with benign PT and 51.7 years in patients with malignant tumors, which closely aligns with findings from other literature. Williams et al. reported that benign tumors were commonly diagnosed between the ages of 20 and 70, while most malignant tumors were identified

between the ages of 40 and 70 [13], which is consistent with our findings (Figure 2). As shown in Figure 1, the onset age of females appears to be earlier than that of male. This difference may be attributed to the increasing life and work pressures faced by women in modern society, leading to more frequent instances of staying up late. Additionally, women may experience higher levels of negative emotions, such as tension, anxiety, loneliness, depression, and irritability compared to men. Disturbances in the body's circadian rhythm, endocrine imbalances, internal environment disruptions, and weakened immunity can also contribute to the development of tumors.

The latest histological classification of salivary gland tumors according to the WHO 2017 version identifies 20 types of malignant tumors and 11 types of benign tumors. Current literature reports suggest that approximately 80% of parotid gland tumors are benign [14], while malignant tumors account for about 15%–30% of parotid gland tumors. Among benign PT, pleomorphic adenoma is the most common type, followed by Warthin tumor [10]. In contrast, the most common malignant parotid tumor is mucoepidermoid carcinoma, followed by adenoid cystic carcinoma [2]. The common pathological types observed in benign tumors were consistent with the results of our study. However, the results of malignant tumors differ from those reported by other research teams, which can be attributed to the small sample size of malignant tumors in this study.

Moreover, there exists a certain correlation between gender and both benign and malignant PT. Several studies on salivary gland tumors have shown a higher prevalence of females compared to males, both benign and malignant [8,13]. Ito et al. [10] found that females accounted for a larger proportion of patients with benign PT (58.5%), while males were more predominant among those with malignant tumors (52.2%). Moreover, patients with benign PT were generally young women, while patients with malignant tumors were typically older men [10]. Gender differences in histopathological types are also evident in parotid gland tumors. For example, Warthin tumors exhibit a significant male predominance (Table 1), which De Ru and Laurence et al. believe may be associated with long-term smoking [15,16]. Pleomorphic adenoma and basal cell adenoma were more frequently observed in women. Among malignant tumors, mucoepidermoid carcinoma and adenoid cystic carcinoma showed a higher incidence in women (Table 1).

The clinical characteristics of parotid gland tumors primarily manifest as local masses in the parotid region. Patients typically do not experience significant subjective symptoms, and most of the tumors are often discovered incidentally during physical examinations or by patients themselves inadvertently, occasionally with symptoms such as pain and facial nerve paralysis [17]. According to the Maahs GS team [4], in 93.9% of the cases they studied, the mass was identified through physical examination by palpating the parotid region. The history and symptoms of the patients are of certain value in the diagnosis of benign and malignant PT. Benign tumors tend to be concealed and exhibit slow, painless growth with good mobility, no adhesion to the surrounding tissues, and have smooth or nodular surfaces. Malignant tumors tend to exhibit rapid growth, invasive characteristics, or adhesion

to surrounding tissues. They can significantly invade nerves, leading to neurological dysfunction, pain, facial paralysis, tongue numbness, and other symptoms. At the initial visit, a slow-growing tumor is generally considered benign, such as pleomorphic adenoma. However, certain low-grade malignant tumors may initially exhibit slow growth similar to benign tumors, making it more challenging to differentiate them from benign tumors as the disease progresses. Therefore, while medical history and physical examination can be used for preliminary identification of tumors, their value is limited [18]. Comprehensive consideration, in combination with imaging examination and intraoperative rapid frozen pathology, is necessary for accurate diagnosis and treatment planning.

For patients, early diagnosis and early treatment are crucial to improve their physical health and the quality of life. The continuous advancements in ultrasound technology have significantly enhanced its resolution and diagnostic capabilities. Ultrasound offers several advantages, including its cost-effectiveness, convenience, rapidity, high repeatability, and absence of radiation exposure. It enables clinicians to identify the presence of space-occupying lesions in the parotid gland, distinguish between cystic and solid components, and evaluate the extent of the lesion, tumor morphology, and boundaries. Additionally, color Doppler imaging can be used to observe the edge and internal blood flow of the lesion. Ultrasound has emerged as the preferred diagnostic tool in the differential diagnosis of parotid masses [19]. According to literature reports, the detection rate of parotid mass using ultrasound is 100% [20]; thus, Ultrasonic diagnosis provides a significant reference for clinical diagnosis and treatment. This study concludes that four ultrasonic features, namely tumor boundary, shape, echo distribution, and the presence of obvious blood flow signals hold high diagnostic value in distinguishing between benign and malignant PT. The specificity, sensitivity, and accuracy of color ultrasound in distinguishing between benign and malignant tumors were found to be 96.53% (250/259), 69.23% (63/91), and 89.43% (313/350), respectively, which were similar to the results of Rzepakowska A et al. [21]. In clinical practice, if ultrasound reveals malignant signs in a parotid gland tumor, such as unclear boundary, irregular shape, calcification, and obvious blood flow signals, a high suspicion of malignancy should be raised. Generally, enhanced CT or enhanced MRI combined with ultrasound is required to improve the accuracy of preoperative examinations and provide guidance for clinicians' decision-making before surgery. In addition, intraoperative rapid frozen pathology is currently considered the most effective method for rapid intraoperative diagnosis of PT. Its accuracy surpasses that of a clinical examination, imaging tests, and fine-needle aspiration biopsy. Intraoperative rapid frozen pathology provides rapid and valuable assistance in determining the benign or malignant nature of the parotid gland tumor, thus aiding clinicians in formulating individualized surgical programs. However, it is important to note that there is still a small probability of diagnostic deviation, which underscores the need for close communication between surgeons and pathologists.

Surgery remains the primary treatment approach for parotid gland tumors. For benign tumors, partial parotidectomy with facial

nerve preservation is commonly performed. If the tumor tissue is large or involves the deep lobe of the parotid gland, complete removal of the parotid gland may be necessary to ensure adequate surgical boundaries and minimize the risk of capsule rupture, thus reducing the likelihood of tumor recurrence. Capsular rupture during surgical resection and positive surgical margins can increase the risk of tumor recurrence. For parotid gland malignancies, the primary surgical objective is complete tumor resection. Due to the often incomplete capsule of malignant tumors, simple tumor resection can lead to residual tumors and small metastases. Therefore, complete parotidectomy or subtotal parotidectomy is typically performed. Depending on the specific situation, post-operative radiotherapy and chemotherapy may be recommended to improve the chances of cure and extend survival time. Adjuvant radiotherapy has been shown to be effective in improving local control and overall survival rates [22].

## CONCLUSION

In conclusion, parotid gland tumors exhibit complex biological characteristics, and comprehensive consideration of their pathogenic characteristics, clinical features, and imaging findings is crucial for accurate diagnosis. Color Doppler ultrasonography plays a significant role in diagnosing PT with its high diagnostic accuracy, thus providing valuable evidence for differentiating between benign and malignant PT and aiding in the clinical selection of individualized surgical programs.

## AUTHOR CONTRIBUTIONS

**Wen Gao:** Writing—original draft (equal); writing—review and editing (equal). **Lifei Feng:** Data curation (equal). **Zishi Huang:** Formal analysis (equal). **Duoxuan Chen:** Data curation (equal). **Wei Guo:** Conceptualization (equal). **Gaofei Yin:** Validation (equal). **Yang Zhang:** Funding acquisition (equal); project administration (equal). **Zhigang Huang:** Project administration (equal); supervision (equal).

## ACKNOWLEDGMENTS

The authors wish to thank the individuals who participated in this study. This work was supported by National Natural Science Foundation of China (No. 82072997), and Beijing Municipal Science and Technology Commission (No. Z221100007422045).

## CONFLICT OF INTEREST STATEMENT

All authors have read the manuscript and approved its submission for publication. All authors declare no conflicts of interest.

## DATA AVAILABILITY STATEMENT

The datasets generated and/or analyzed during the current study are not publicly available due to protection of the privacy of patients, but are available from the corresponding author on reasonable request.

## ETHICS STATEMENT

This study was approved by the Human Ethics Committee of Beijing Tongren Hospital, Capital Medical University.

## REFERENCES

- Seethala RR, Stenman G. Update from the 4th edition of the World Health Organization classification of head and neck tumours: tumors of the salivary gland. *Head Neck Pathol.* 2017;11(1):55-67.
- Lyu HX, Wang ZR, Gao YQ, Yu M, Li BQ, Zhang ZB. [Clinical pathologic analysis on 3 724 cases of salivary gland tumors]. *Zhonghua Kou Qiang Yi Xue Za Zhi.* 2019;54(1):10-16. Chinese.
- Zhao ZG, Gao D, Wang J, Zhang LP. [Retrospective analysis of 896 cases of parotid gland tumor]. *Shang Hai Kou Qiang Yi Xue.* 2017;26(6):605-609. Chinese.
- Maahs GS, Oppermann Pde O, Maahs LG, Machado Filho G, Ronchi AD. Parotid gland tumors: a retrospective study of 154 patients. *Braz J Otorhinolaryngol.* 2015;81(3):301-306.
- Yan M, Xu D, Chen L, Zhou L. Comparative study of qualitative and quantitative analyses of contrast-enhanced ultrasound and the diagnostic value of B-mode and color Doppler for common benign tumors in the parotid gland. *Front Oncol.* 2021;11:669542.
- Ellis GL, Auclair PL, Gnepp DR, eds. *Surgical Pathology of the Salivary Glands.* WB Saunders; 1991.
- Yu G, Ma D. [Research status of salivary gland diseases in China]. *Chin J Stomatology.* 2003, 38(2): 81-84. Chinese.
- Eveson JW, Cawson RA. Salivary gland tumours. A review of 2410 cases with particular reference to histological types, site, age and sex distribution. *J Pathol.* 1985;146(1):51-58.
- Spiro RH. Salivary neoplasms: overview of a 35-year experience with 2,807 patients. *Head Neck Surg.* 1986;8(3):177-184.
- Takahama A, De Almeida OP, Kowalski LP. Parotid neoplasms: analysis of 600 patients attended at a single institution. *Braz J Otorhinolaryngol.* 2009;75(4):497-501.
- Ito FA, Ito K, Vargas PA, de Almeida OP, Lopes MA. Salivary gland tumors in a Brazilian population: a retrospective study of 496 cases. *Int J Oral Maxillofac Surg.* 2005;34(5):533-536.
- Comprehensive Analysis of Parotid Mass: A Retrospective Study of 369 Cases.
- Williams NP, Boyd DL, Choy L, Hanchard B. Salivary gland lesions: a Jamaican perspective. *W Indian Med J.* 2000;50:62-65.
- Lin CC, T sai MH, Huang CC, Hua CH, T seng HC, Huang ST. Parotid tumors: a 10 year experience. *Am J Otolaryngol.* 2008;29(2): 94-100.
- de Ru JA, Plantinga RF, Majoor MH, et al. Warthin's tumour and smoking. *B-ENT.* 2005;1(2):63-66.
- Psychogios G, Vlastos I, Thölken R, Zenk J. Warthin's tumour seems to be the most common benign neoplasm of the parotid gland in Germany. *Eur Arch Oto-Rhino-Laryngol.* 2020;277(7): 2081-2084.
- Roh JL, Kim HS, Park CI. Randomized clinical trial comparing partial parotidectomy versus superficial or total parotidectomy [J]. *Br J Surg.* 2007, 94(9): 1081-1087.
- Bisdas S, Baghi M, Wagenblast J, et al. Differentiation of benign and malignant parotid tumors using deconvolution-based perfusion CT imaging: feasibility of the method and initial result. *Eur J Radiol.* 2007, 64(2): 258-265.
- Stoia S, Băciuț G, Lenghel M, et al. Ultrasonography techniques in the preoperative diagnosis of parotid gland tumors - an updated review of the literature. *Med Ultrason.* 2021;23(2):194-202.
- Huang HT, Liu HW, Wang R, Hu M. [A retrospective analysis of 412 cases of malignant tumors in parotid gland]. *Shang Hai Kou Qiang Yi Xue.* 2014;23(3):340-345. Chinese.

21. Rzepakowska A, Osuch-Wójcikiewicz E, Sobol M, Cruz R, Sielska-Badurek E, Niemczyk K. The differential diagnosis of parotid gland tumors with high-resolution ultrasound in otolaryngological practice. *Eur Arch Oto-Rhino-Laryngol.* 2017;274(8): 3231-3240.
22. Takahama Junior A, Almeida OP, Kowalski LP. Parotid neoplasms: analysis of 600 patients attended at a single institution. *Braz J Otorhinolaryngol.* 2009;75(4):497-501.

**How to cite this article:** Gao W, Feng L, Huang Z, et al. A retrospective analysis of 350 cases of parotid gland tumors and the value of ultrasound in the diagnosis of benign and malignant parotid gland tumors. *Eye & ENT Res.* 2024;1(1): 56-63. <https://doi.org/10.1002/eer3.7>