

## CASE REPORTS

# A rare case of ‘Dog Bite Meningitis’ in a healthy adult

Peter Anderyas, Julia Freckelton, James J Gome, Satish Nagarajah, Nuwan Dhanushka Miththinda Jasenthu Kankanamage\*

Department of Medicine, South West Healthcare, Warrnambool Clinical School, Deakin University, Victoria, Australia

**Received:** June 3, 2020

**Accepted:** June 15, 2020

**Online Published:** June 23, 2020

**DOI:** 10.5430/crim.v7n2p22

**URL:** <https://doi.org/10.5430/crim.v7n2p22>

## ABSTRACT

*Capnocytophaga canimorsus* is a commensal in the normal gingival flora of canine and feline species and is reported to cause infections in humans following bites by these species with potentially serious consequences, especially in the immunocompromised. Here we report a case of a 58-year-old healthy woman presenting with uncomplicated meningitis following a seemingly minor bite by her pet dog. With early detection and appropriate antibiotic therapy she had an uneventful recovery. Our case reports the possibility of this organism infecting an otherwise healthy, immunocompetent adult and the importance of being vigilant of such rare presentations by clinicians which will help to deliver appropriate therapy early to avoid any serious complications.

**Key Words:** Dog bite, Meningitis, *Capnocytophaga canimorsus*

## 1. INTRODUCTION

*Capnocytophaga canimorsus* is a gram-negative bacillus of the family Flavobacteriaceae and is a commensal microbe found in the oral cavity of dogs and cats.

Human infection with *C.canimorsus* is rare, and is often associated with dog or cat bites. A retrospective population survey in the Netherlands found a yearly incidence of *C.canimorsus* infections of 0.67 per million.<sup>[1]</sup> Asplenia, being immunocompromised, heavy alcohol use, smoking and increased age have all been identified as risk factors for *C.canimorsus* infection.<sup>[2]</sup> However, it has been identified as an emerging pathogen in immunocompetent individuals too with a case fatality rate of 30%.<sup>[3]</sup> The virulence of *C.canimorsus* can, in part, be explained by its ability to inhibit the bactericidal ability of macrophages.<sup>[4]</sup> Adding to its virulence is the capsular polysaccharide on the surface of the *C.canimorsus* bacterium, which helps defend against the innate immune system.<sup>[5]</sup>

In addition to severe sepsis, its presentations can include meningitis, infective endocarditis, gangrene of the digits or extremities, and eye infections.<sup>[2]</sup>

## 2. CASE PRESENTATION

A 58-year-old previously well woman presented to the emergency department with a severe headache in the setting of a seemingly minor bite by her pet dog four days earlier, which she had ignored. Two days after the dog bite, she had developed systemic symptoms including headache, myalgia, subjective fevers and rigors. She had no visual disturbance, rash, photophobia nor other exposure history. She smoked and had alcohol only occasionally.

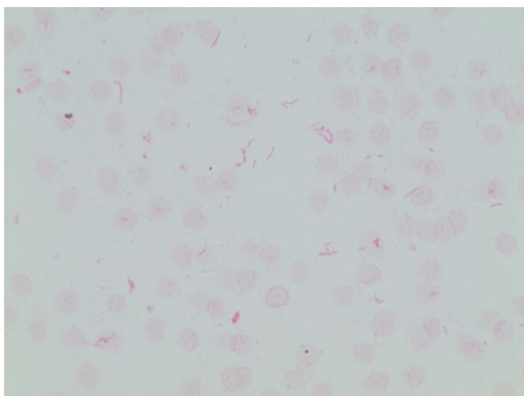
On arrival to the emergency department she was febrile to 39.1 degrees Celsius. She had three small, scabbed puncture marks on her right wrist with no evidence of local infection. She had significant neck stiffness and rest of her system examination was normal including the neurological examina-

\*Correspondence: Nuwan Dhanushka Miththinda Jasenthu Kankanamage; Email: [jkndmiththinda@gmail.com](mailto:jkndmiththinda@gmail.com); Address: Department of Medicine, South West Healthcare, Warrnambool Clinical School, Deakin University, Victoria, Australia.

tion.

Initial investigations showed a leukocytosis of  $19.9 \times 10^9/L$  with a neutrophil predominance ( $18.7 \times 10^9/L$ ) and a c-reactive protein of 338 mg/L. Computed tomography scan of the brain was unremarkable. Cerebrospinal fluid (CSF) analysis was suggestive of bacterial meningitis with white cell  $280 \times 10^6/L$ , polymorphs  $230 \times 10^6/L$  and protein 0.95 g/L.

After 48 hours, gram-negative bacilli of *C. canimorsus* species were detected in the aerobic bottle of one of four blood cultures (see Figure 1). Despite extended incubation of 7 days no other blood cultures or the CSF culture grew *C. canimorsus*. The patient's condition was complicated by a moderate asymptomatic hyponatraemia down to 125 mmol/L, which was clinically and biochemically consistent with syndrome of inappropriate antidiuretic hormone secretion secondary to meningitis, which responded to fluid restriction. Her albumin was low at 28 g/L keeping with sepsis but had normal globulin levels throughout. Immunoglobulin subsets were not done as there was no history of recurrent infections to suggest immunoglobulin deficiency and patient responded well to antibiotic therapy.



**Figure 1.** *Capnocytophaga canimorsus* detected in blood culture

She was initially commenced on intravenous (IV) piperacillin and tazobactam as empiric treatment for sepsis, and then in light of the CSF biochemistry changed to IV benzylpenicillin, IV ceftriaxone and IV vancomycin. She also received IV dexamethasone. The antibiotic regimen was de-escalated to ceftriaxone monotherapy upon isolation of *C. canimorsus*, which was continued for a total of 14 days with the support of a hospital in the home program. The patient made a complete and uneventful recovery.

### 3. DISCUSSION

Human infections of *C. canimorsus* are commonly associated with either immunocompromised states or risk factors for immune suppression.<sup>[1,2]</sup> Our patient was healthy and

Published by Sciedu Press

didn't have significant risk factors compromising her immunity, highlighting the high virulence of *C. canimorsus* and the importance of considering infection by it even in the immunocompetent patients.

*C. canimorsus* is a fastidious bacteria; it has been demonstrated to have a mean time to positive blood culture of 4 days.<sup>[6]</sup> Therefore it is critical that in patients suspected of this infection, cultures be kept for an extended period of incubation. In our case the blood culture became positive after 48 hours. Similarly CSF cultures require extended incubation with a median time to positive culture of 5 days.<sup>[6]</sup> In our case despite extended incubation up to 7 days, CSF remained sterile. In suspicious but culture negative cases PCR testing can be used alternatively.

A third of *Capnocytophaga* species produce beta lactamase. Therefore, penicillin in combination with beta-lactamase inhibitor has been the recommended empiric therapy for patients suspected of *Capnocytophaga* infection.<sup>[7]</sup> This treatment regimen is supported by a recent systematic review demonstrating initial treatment with penicillin therapy in combination with beta lactamase inhibitor as independently protective against septic shock and fatal outcomes.<sup>[3]</sup> They are also shown to be susceptible to extended spectrum cephalosporins, clindamycin and ciprofloxacin.<sup>[7]</sup> Our patient was managed with a course of IV Ceftriaxone with uncomplicated recovery, which is part of standard meningitis treatment. Prophylactic antibiotics are recommended following high-risk dog bites such as bites in the hands like in our case.<sup>[8]</sup> We believe had she not ignored this 'minor' dog bite and sought medical attention early this untoward complication could have been prevented with prophylactic antibiotics with beta lactamase cover such as amoxicillin/clavulanate.

This case illustrates the importance of considering *C. canimorsus* as a possible pathogenic organism in patients with meningitis, particularly in the setting of a recent dog or cat bite. Awareness of this infection allows clinicians to ensure blood and CSF cultures are incubated for an extended time for correct identification, and an adequate antibiotic cover is received to avoid any serious complications. Furthermore, it highlights the importance of using appropriate prophylactic antibiotics in case of high-risk animal bites to prevent unwanted complications even in otherwise healthy individuals.

### ACKNOWLEDGEMENTS

Authors would like to acknowledge Hassan Farah, Chief Scientist Microbiology of Dorevitch pathology for providing us with the image of *Capnocytophaga canimorsus* isolated in our patient's blood culture.

### CONFLICTS OF INTEREST DISCLOSURE

The authors have declared no conflicts of interest.

**REFERENCES**

- [1] van Dam AP, Jansz A. Capnocytophaga canimorsus infections in The Netherlands: a nationwide survey. *Clinical Microbiology and Infection*. 2011 Feb; 17(2): 312-5. PMID:20167010. <https://doi.org/10.1111/j.1469-0691.2010.03195.x>
- [2] Pers C, Gahrn-Hansen B, Frederiksen W. Capnocytophaga canimorsus Septicemia in Denmark, 1982-1995: Review of 39 Cases. *Clinical Infectious Diseases*. 1996 Jul 1; 23(1): 71-5. PMID:8816132. <https://doi.org/10.1093/clinids/23.1.71>
- [3] Mader N, Lührs F, Langenbeck M, et al. Capnocytophaga canimorsus - a potent pathogen in immunocompetent humans - systematic review and retrospective observational study of case reports. *Infectious Diseases*. 2019 Nov 9; 52(2): 65-74. PMID:31709860. <https://doi.org/10.1080/23744235.2019.1687933>
- [4] Mally M, Paroz C, Shin H, et al. Prevalence of Capnocytophaga canimorsus in dogs and occurrence of potential virulence factors. *Microbes and Infection*. 2009 Apr; 11(4): 509-14. PMID:19285152. <https://doi.org/10.1016/j.micinf.2009.02.005>
- [5] Renzi F, Ittig SJ, Sadovskaya I, et al. Evidence for a LOS and a capsular polysaccharide in Capnocytophaga canimorsus. *Scientific Reports*. 2016 Dec; 6(1). PMID:27974829. <https://doi.org/10.1038/srep38914>
- [6] Hansen M, Crum-Cianflone NF. Capnocytophaga canimorsus Meningitis: Diagnosis Using Polymerase Chain Reaction Testing and Systematic Review of the Literature. *Infectious Diseases and Therapy*. 2019 Jan 31; 8(1): 119-36. PMID:30706413. <https://doi.org/10.1007/s40121-019-0233-6>
- [7] Roscoe DL, Zemcov SJ, Thornber D, et al. Antimicrobial susceptibilities and beta-lactamase characterization of Capnocytophaga species. *Antimicrobial Agents and Chemotherapy*. 1992 Oct 1; 36(10): 2197-200. PMID:1444299. <https://doi.org/10.1128/AAC.36.10.2197>
- [8] Ellis R, Ellis C. Dog and Cat Bites. *American Family Physician [Internet]*. 2014 [cited 2020 Jun 13]; 90(4): 239-43. Available from: <https://www.aafp.org/afp/2014/0815/p239.html#aafp20140815p239-b10>