


DOI: <https://doi.org/10.17816/uroved72148>

Features of the extraction of foreign bodies from the lower urinary tract

© Gocha Sh. Shanava^{1, 2}, Michail S. Mosoyan^{2, 3}, Artur M. Grabsky^{4, 5}, Karen G. Arzumanyan^{4, 5}¹ St. Petersburg I.I. Dzhanelidze Research Institute of Emergency Medicine, Saint Petersburg, Russia;² Almazov National Medical Research Centre, Saint Petersburg, Russia;³ Academician I.P. Pavlov First St. Petersburg State Medical University, Saint Petersburg, Russia;⁴ Yerevan Mkhitar Heratsi State Medical University, Yerevan, Armenia;⁵ Medical Center "Izmirlian", Yerevan, Armenia

BACKGROUND: Foreign bodies introduced by patients into the bladder and urethra are relatively rare in clinical practice. As a result, there is insufficient information in the scientific literature regarding methods of extracting foreign bodies from the urinary tract.

AIM: determination of the optimal methods for extracting foreign bodies from the urethra and bladder.

MATERIALS AND METHODS: Foreign bodies of the lower urinary tract were removed in 21 patients: 15 (71.4%) men and 6 (28.6%) women. Foreign bodies were found in the urethra in 7 (33.3%) patients and in the bladder in 14 (66.7%) patients. Removal of foreign bodies from the urethra and bladder was performed endoscopically or during open surgery.

RESULTS: Removal of stabbing, cutting and glass objects from the urinary tract in 9 patients was performed during open surgery. Foreign bodies with even smooth edges were removed in 12 patients under urethrocystoscopic control. At the same time, in two patients, coagulated suppositories were first fragmented in the bladder cavity, and then removed in parts. Cystolithotripsy was performed in one patient with a suppository inlaid with calculus before fragmentation.

CONCLUSIONS: Foreign bodies with sharp edges or made of glass are safer to be removed from the lower urinary tract during open surgery. Foreign bodies with a smooth and even surface are optimally removed endoscopically. Long and bulky foreign objects that can be fragmented in the bladder cavity are best removed in parts. When foreign bodies are encrusted with large calculi, cystolithotripsy should be performed before their endoscopic extraction.

Keywords: foreign bodies of the lower urinary tract; endoscopic extraction; cystotomy; cystolithotripsy.

To cite this article:

Shanava GSh, Mosoyan MS, Grabsky AM, Arzumanyan KG. Features of the extraction of foreign bodies from the lower urinary tract. *Urology reports (St. Petersburg)*. 2021;11(3):213-218. DOI: <https://doi.org/10.17816/uroved72148>

DOI: <https://doi.org/10.17816/uroved72148>

Особенности извлечения инородных тел из нижних мочевыводящих путей

© Г.Ш. Шанава^{1, 2}, М.С. Мосоян^{2, 3}, А.М. Грабский^{4, 5}, К.Г. Арзуманян^{4, 5}¹ Санкт-Петербургский научно-исследовательский институт скорой помощи им. И.И. Джанелидзе, Санкт-Петербург, Россия;² Национальный медицинский исследовательский центр им. В.А. Алмазова, Санкт-Петербург, Россия;³ Первый Санкт-Петербургский государственный медицинский университет им. акад. И.П. Павлова, Санкт-Петербург, Россия;⁴ Ереванский государственный медицинский университет им. Мхитара Гераци, Ереван, Республика Армения;⁵ Медицинский центр «Измирлян», Ереван, Республика Армения

Введение. Инородные тела, введенные пациентами себе в мочевой пузырь и уретру, в клинической практике встречаются относительно редко. Вследствие этого в научной литературе представлено недостаточно сведений относительно способов извлечения инородных тел из мочевыводящих путей.

Цель исследования. Определение оптимальных способов извлечения инородных тел из уретры и мочевого пузыря.

Материалы и методы. У 21 пациента, среди которых 15 (71,4 %) мужчин и 6 (28,6 %) женщин, извлекали инородные тела из нижних мочевыводящих путей. У 7 (33,3 %) пациентов инородные тела находились в уретре, у 14 (66,7 %) — в мочевом пузыре. Инородные тела из уретры и мочевого пузыря удаляли эндоскопическим способом или в ходе открытого хирургического вмешательства.

Результаты. Извлечение колющих, режущих и стеклянных предметов из мочевыводящих путей у 9 пациентов проводили в ходе открытых операций. Инородные тела с ровными гладкими краями у 12 пациентов удаляли под уретроцистоскопическим контролем. При этом у двоих пациентов свернувшиеся свечи вначале фрагментировали в полости мочевого пузыря, а затем извлекали по частям. Одному пациенту с инкрустированной конкрементом свечой перед ее фрагментацией выполняли цистолитотрипсию.

Выводы. Инородные тела, имеющие острые края или состоящие из стекла, безопаснее извлекать из нижних мочевыводящих путей при проведении открытого хирургического вмешательства. Инородные тела, имеющие гладкую и ровную поверхность оптимально удалять эндоскопическим способом. Длинные и объемные инородные предметы, которые можно фрагментировать в полости мочевого пузыря, целесообразнее удалять по частям. При инкрустации инородных тел крупными конкрементами перед эндоскопическим их извлечением следует выполнять цистолитотрипсию.

Ключевые слова: инородные тела нижних мочевыводящих путей; эндоскопическое извлечение; цистотомия; цистолитотрипсия.

Как цитировать:

Шанава Г.Ш., Мосоян М.С., Грабский А.М., Арзуманян К.Г. Особенности извлечения инородных тел из нижних мочевыводящих путей // Урологические ведомости. 2021. Т. 11. № 3. С. 213–218. DOI: <https://doi.org/10.17816/uroved72148>

INTRODUCTION

Foreign bodies inserted by patients into their urinary tract are relatively rare in the practice of urologists [1]. In most cases, patients insert foreign bodies through the urethra [1–5]. Much less often, swallowed foreign bodies enter the bladder from the gastrointestinal tract as a result of hollow organ perforations [6, 7]. In addition, penetration of objects with sharp edges into the urinary tract is known as a result of their migration from the penis, scrotum, or anterior abdominal wall, where these foreign bodies were initially placed by patients themselves [8, 9]. In extremely rare cases, fragments of medical instruments or dressings are left and forgotten in the bladder after endoscopic interventions [10, 11]. The insertion of foreign bodies, especially those with stabbing or cutting edges, is often accompanied by lower urinary tract trauma, requiring surgical intervention [6–9].

The motivation of adult patients who inserted or stuck foreign bodies into the urinary tract is different. Some do it deliberately to obtain sexual satisfaction by inserting objects of various shapes and sizes into their urethra [1, 12, 13]. Some patients with mental disorders, who inserted, stuck, or swallowed various foreign bodies, are not always able to explain the reason for their actions. Another part explains the insertion of foreign objects by ordinary curiosity or a desire to enhance erotic sensations during masturbation [1, 2]. Subsequently, in connection with pain, urinary disorders, hematuria, or the development of inflammatory complications, patients seek medical help [1, 2, 5, 12, 14, 15]. After establishing the diagnosis, urologists face the question of choosing a method for extracting a foreign object from the urinary tract [4, 12]. The presence of foreign bodies in the urinary tract is rare, thus generalized information in the scientific

literature regarding the advantages and disadvantages of different extraction methods is insufficient. The publications reflect only individual clinical cases describing the removal of various foreign objects from the urethra or the bladder [1, 15].

This study aimed to determine the optimal methods for extracting foreign bodies of various shapes, sizes, and physical properties from the urethra and the bladder.

MATERIALS AND METHODS

From 2003 to 2020 at the I.I. Janelidze St. Petersburg Research Institute of Emergency Medicine, various foreign bodies were removed from the lower urinary tract from 17 patients. During this period, at the Izmirlian Medical Center (Yerevan, Republic of Armenia), foreign bodies were removed from the bladder of 4 people. Thus, in two medical institutions, foreign bodies from the urinary tract were removed in 21 patients, including 15 (71.4%) men and 6 (28.6%) women, who were over 18 years old. In 7 (33.3%) patients, foreign bodies were in the urethra and 14 (66.7%) in the bladder. A description of foreign bodies in the lower urinary tract is presented in Table.

The most frequent complaint of patients during hospitalization was pain, which was noted by 16 (76.2%) patients. Some patients reported pain in the urethra, others in the perineum or suprapubic region. Dysuria was reported by 14 (66.7%) people and 8 (38.1%) had hematuria. Three patients were admitted with acute urinary retention. In 11 (52.4%) patients, foreign objects caused inflammatory complications; 4 (19.0%) had urethritis and 7 (33.3%) had cystitis.

When collecting anamnesis, in 9 (42.9%) patients, the reason for foreign body insertion into the urinary tract was the desire to strengthen erection and improve sexual

Table. Foreign bodies are in the lower urinary tract ($n = 21$)

Таблица. Инородные тела в нижних мочевыводящих путях ($n = 21$)

Foreign body	Men ($n = 15$)		Women ($n = 6$)	
	n	%	n	%
Mercury glass thermometer	1	4.8	1	4.8
Glass pipette	–	–	1	4.8
Cake candle	2	9.5	1	4.8
Nails	2	9.5	–	–
Sewing needles	3	14.3	–	–
Pin	–	–	2	9.5
Tablet battery	1	4.8	–	–
Oval metal bar	2	9.5	1	4.8
Beauty stick	1	4.8	–	–
Metal ball	1	4.8	–	–
Surgical needle	1	4.8	–	–
Fragment of Dormia basket	1	4.8	–	–
Total	15	71.4	6	28.6

sensations. Two men injected foreign bodies (beauty stick and an oval metal rod) for an independent bougienage of the urethra. 7 (33.3%) patients could not name the circumstances, reasons, and timing of foreign body insertions. Foreign bodies in the bladder were detected in 3 (14.3%) patients 3–8 months after previous surgical interventions, which were performed in various hospitals.

Foreign bodies were diagnosed during the collection of complaints, physical, and ultrasound examination and according to plain urography, spiral computed tomography, urethrocytography, and urethrocytostomy.

Foreign body removal from the urethra and bladder was endoscopically performed or during open surgery. Endoscopic removal was performed in the course of urethrocytostomy, during which foreign objects were grasped with endoforceps or a Dormia basket and then removed from the lower urinary tract. When conducting open surgical interventions, the bladder or penis was revised together with the urethra, from which foreign bodies were removed.

All patients received antibacterial and anti-inflammatory therapy intraoperatively and postoperatively. After the foreign body removal, the bladder was drained with a urethral catheter or a suprapubic cystostomy application.

RESULTS

Removal of piercing, cutting, and glass objects were performed in the course of open surgeries. Thus, 4 (19.0%) patients, 3 had sewing needles (Fig. 1) and 1 had nails inserted into the penis, from where sharp objects partially migrated into the urethra, underwent open surgical interventions. Surgeries to remove needles and nails were performed under X-ray control. After removing the needles from the urethra, a Foley urethral catheter was installed in 3 (14.3%) patients for 9–12 days. One patient, who damaged the hanging part of the urethra with two nails in three places, underwent a trocar cystostomy along with a urethral catheter installation. Urethra defects after surgical treatment were sutured with absorbable sutures. After 8 days, the urethral catheter was removed. After 4 weeks, the cystostomy tube was removed after urethrography and confirmation of the patency and integrity of the urethra.

A patient with a tablet-shaped battery in the urethra, found during urethrography (Fig. 2), underwent endoscopic surgery. During urethroscopy, capturing the battery with endoscopic instruments in the urethra was impossible. Thus, the battery was displaced into the bladder cavity. The battery was grasped and removed from the bladder using the Dormia basket.

The beauty stick and the oval metal rod, inserted by patients themselves for bougienage of the urethra, were removed during urethroscopy using endoscopic forceps. Grasping the distal ends of the beauty stick and the metal rod with forceps in the posterior urethra, they were gently brought down to the external urethral opening.

Foreign bodies with smooth edges, such as oval metal rods, a ball, a pin, and a fragment of the Dormia basket, were removed from the bladder under cystoscopic control using endoscopic gripping instruments.

Thin candles inserted through the urethra into the bladder were also removed endoscopically. In this case, one candle was entirely removed by grasping its end with endoscopic forceps. In 2 patients, the candles, which were in a folded state in the bladder, were encrusted with calculi (Fig. 3). One candle was 1.0 × 1.5 cm in size. He underwent cystolithotripsy. Coiled candles in the bladder cavity were fragmented in both patients. Using endoscopic forceps, candle fragments were removed in parts from the lower urinary tract.

Mercury thermometers (Fig. 4), glass pipette, surgical needle, and nail in the bladder were removed during open surgery. For this, the bladder was opened extraperitoneally through the suprapubic access. The thermometers and glass pipette were entirely removed from the bladder cavity.

After removing the thermometer and glass pipette, the women's bladder was drained using a urethral catheter. The bladder wound was tightly sutured. A suprapubic cystostomy was installed in a man suffering from prostatic hyperplasia after the removal of a mercury thermometer. Two months after the transurethral resection of benign prostatic hyperplasia, the cystostomy tube was removed.

During the endoscopic extraction of the surgical needle and nail, wherein one was located in the bladder and the other in the pre-bladder tissue, technical difficulties arose with their safe removal. Therefore, open surgery on the bladder was performed under X-ray control.

DISCUSSION

Several factors influenced the choice of foreign body extraction method from the urinary tract. We took into account the size, shape, and the foreign body material, as well as the possibility of fragmentation of long and voluminous objects and the presence of sharp ends, as well as their location in the urinary tract. The peculiarity of the foreign body location was of great importance. Objects, which, in one part, were localized in the urinary tract and the other in the surrounding tissues, were removed during open surgeries under X-ray control. Objects with piercing and cutting ends or glass were also removed during open surgical interventions to avoid additional urinary tract damage by the sharp edges of these foreign bodies or their fragments. All foreign bodies with a smooth surface were removed endoscopically. Long or bulky objects that could be fragmented in the bladder cavity under cystoscopic control were removed from the urinary tract in parts. Open surgery was performed for large foreign bodies that are impossible to fragment, which was technically difficult to remove endoscopically. Cystolithotripsy was performed in a foreign body, covered with calculi that increased its volume and size in the bladder.

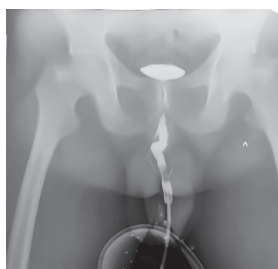


Fig. 1. Needles were passed through the soft tissue into the urethra

Рис. 1. Иглы, проведенные через мягкие ткани в уретру

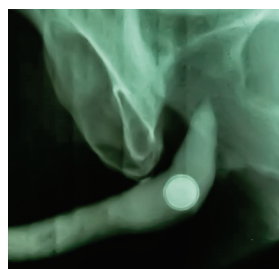


Fig. 2. A pill-shaped battery is in the urethra

Рис. 2. Батарейка в форме таблетки в уретре

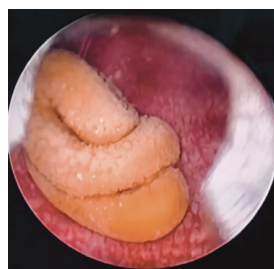

Fig. 3. Rolled up inlaid candle is in the cavity of the bladder

Рис. 3. Свернутая инкрустированная свеча в полости мочевого пузыря

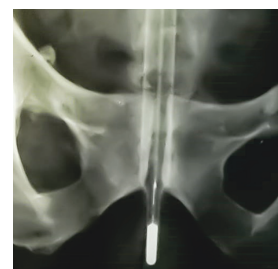


Fig. 4. The Mercury thermometer is in the bladder

Рис. 4. Ртутный термометр в полости мочевого пузыря

cavity, before its endoscopic removal. Endoscopic extraction of foreign bodies from the bladder in women was much easier and faster than in men due to the anatomical aspects of the urethra.

CONCLUSIONS

Foreign bodies of sharp edges or made of glasses are safer to be removed from the lower urinary tract during open surgery. Foreign bodies with a smooth and even surface are optimally removed endoscopically. Long and bulky

foreign bodies, in which extraction is complicated, but can be fragmented in the bladder cavity, are more expediently removed in parts. When foreign bodies are encrusted with large calculi, cystolithotripsy should be performed before their endoscopic extraction.

ADDITIONAL INFORMATION

Funding. The study had no external funding.

Conflict of interest. The authors declare no conflict of interest.

REFERENCES

1. Prokhorov AV. Diagnosis and treatment of urethral and urinary foreign bodies in adults. *Perm Medical Journal*. 2015;32(6):14–24. (In Russ.) DOI: 10.17816/pmi32614-24
2. Passaro G, Cappa E, Abbesis A, et al. Foreign bodies in urinary bladder: a clinical case. *Urologia*. 2011;78(4):310–313. DOI: 10.5301/RU.2011.8865
3. Ortoglu F, Gurlen G, Altunkol A, et al. A Rare Foreign Material in the Bladder: Piece of Pencil. *Archives of Iranian Medicine*. 2015;(9): 616–617.
4. Elbab TKF, Abdelhamid AM, Galal EM, et al. Management of intravesical self-inflicted sharp objects in children: 10 year single center experience. *J Pediatr Urol*. 2016;12(2):97.e 1–5. DOI: 10.1016/j.jpuro.2015.06.020
5. Yobing Li, Unique Gao, Xiangdong Chen, Shaobo Jiang. Rare foreign body in bladder: A case report. *Medicine (Baltimore)*. 2018;97(17): e0519. DOI: 10.1097/MD.00000000000010519
6. Doganay M, Metin E, Doganay M. Acute abdomen due to a foreign body in the urinary bladder in an adolescent. *J Emerg Med*. 2011;40(4):391–392. DOI: 10.1016/j.jemermed.2009.08.017
7. Mirsa S, Jain V, Ahmad F, et al. Metallic sewing needle ingestion presenting as acute abdomen. *Niger J Clin Pract*. 2013;16(4):540–543. DOI: 10.4103/1119-3077.116879
8. Yi Min Tung J, Sim PY, Tung KH. Gastric banding clip in the urinary bladder. *Urologia*. 2019;86(3):127–129. DOI: 10.1177/0391560319832481
9. Kharbach Y, Tenkorang S, Ahsaini M, et al. Suicide attempt by self-stabbing of the bladder: a case report. *J Med Case Rep*. 2014;8:391. DOI: 10.1186/1752-1947-8-391
10. Castellani D, Gasparri L, Claudini R, et al. Iatrogenic foreign body in urinary bladder: Holmium laser vs. Ceramic, and the winner is. *Int Braz J Urol*. 2019;45(4):853. DOI: 10.1590/S1677-5538.IBJU.2018.0229
11. Cardinale M, Scheiwe C, Boubotte-Salmon F, Laitse-lart P. A rare Foreign Body in the bladder: a surgical dressing as a bladder stone. *Med Sainte Trop*. 2019;29(2):222–224. DOI: 10.1684/mst.2019.0902
12. Mannan A, Anwar S, Oayyum A, Tasneem RA. Foreign bodies in the urinary bladder and their management: a Pakistani experience. *Singapore Med J*. 2011;52(1):24–28.
13. Agarwal M, Aggarwal A, Pandey S, Kumar M. Knotted electric wire in urinary bladder: Can such complex foreign body be retrieved endoscopically! *BMJ Case Rep*. 2018: bcr2018225353. DOI: 10.1136/bcr-2018-225353
14. Hashmi SH, Khan I. Foreign body in urinary bladder: an unusual presentation. *J Ayub Med. Abbottabad*. 2015;27(2):494–495.
15. Nurmuhamedov KN, Radzabov UA. A longtime stay of the foreign body (needle) in the urethra and soft tissues of the perineum in a 10 year boy. *Eksperimental'naya i klinicheskaya urologiya*. 2013;(2):137–138. (In Russ.)

СПИСОК ЛИТЕРАТУРЫ

1. Прохоров А.В. Диагностика и лечение инородных тел уретры и мочевого пузыря у взрослых // Пермский медицинский журнал. 2015. Т. 32. № 6. С. 14–24. DOI: 10.17816/pmi32614-24
2. Passaro G., Cappa E., Abbesis A., et al. Foreign bodies in urinary bladder: a clinical case // Urologia. 2011. Vol. 78, No. 4. P. 310–313. DOI: 10.5301/RU.2011.8865

3. Ortoglu F., Gurlen G., Altunkol A., et al. A Rare Foreign Material in the Bladder: Piece of Pencil // *Archives of Iranian Medicine*. 2015. No. 9. P. 616–617.
4. Elbab T.K.F., Abdelhamid A.M., Galal E.M., et al. Management of intravesical self-inflicted sharp objects in children: 10 year single center experience // *J Pediatr Urol*. 2016. Vol. 12, No. 2. P. 97e 1–5. DOI: 10.1016/j.jpuro.2015.06.020
5. Li Y., Gao U., Chen X., Jiang S. Rare foreign body in bladder: A case report // *Medicine (Baltimore)*. 2018. Vol. 97, No. 17. P. e0519. DOI: 10.1097/MD.00000000000010519
6. Doganay M., Metin E., Doganav M. Acute abdomen due to a foreign body in the urinary bladder in an adolescent // *J Emerg Med*. 2011. Vol. 40, No. 4. P. 391–392. DOI: 10.1016/j.jemermed.2009.08.017
7. Mirsa S., Jain V., Ahmad F., et al. Metallic sewing needle ingestion presenting as acute abdomen // *Niger J Clinic Pract*. 2013. Vol. 16, No. 4. P. 540–543. DOI: 10.4103/1119-3077.116879
8. Yi Min Tung J., Sim P.Y., Tung K.H. Gastric banding clip in the urinary bladder // *Urologia*. 2019. Vol. 86, No. 3. P. 127–129. DOI: 10.1177/0391560319832481
9. Kharbach Y., Tenkorang S., Ahsaini M., et al. Suicide attempt by self-stabbing of the bladder: a case report // *J Med Case Rep*. 2014. Vol. 8. P. 391. DOI: 10.1186/1752-1947-8-391
10. Castellani D., Gasparri L., Claudini R., et al. Iatrogenic foreign body in urinary bladder: Holmium laser vs. Ceramic, and the winner is // *Int Braz J Urol*. 2019. Vol. 45, No. 4. P. 853. DOI: 10.1590/S1677-5538.IBJU.2018.0229
11. Cardinale M., Scheiwe C., Boubotte-Salmon F., Laitselet P. A rare Foreign Body in the bladder: a surgical dressing as a bladder stone // *Med Sainte Trop*. 2019. Vol. 29, No. 2. P. 222–224. DOI: 10.1684/mst.2019.0902
12. Mannan A., Anwar S., Oayyum A., Tasneem R.A. Foreign bodies in the urinary bladder and their management: a Pakistani experience // *Singapore Med J*. 2011. Vol. 52, No. 1. P. 24–28.
13. Agarwal M., Aggarwal A., Pandey S., Kumar M. Knotted electric wire in urinary bladder: Can such complex foreign body be retrieved endoscopically! // *BMJ Case Rep*. 2018. P. bcr2018225353. DOI: 10.1136/bcr-2018-225353
14. Hashmi S.H., Khan I. Foreign body in urinary bladder: an unusual presentation // *J Ayub Med. Abbottabad*. 2015. Vol. 27, No. 2. P. 494–495.
15. Нурмухамедов К.Н., Раджабов У.А. Длительность нахождения инородного тела (иглы) в уретре и мягких тканях промежности у мальчика 10 лет // *Экспериментальная и клиническая урология*. 2013. № 2. С. 137–138.

AUTHORS' INFO

***Gocha Sh. Shanava**, Cand. Sci. (Med.), urologist; address: 3, Budapeshtskaya str., 192242, Saint Petersburg, Russia; eLibrary SPIN: 1706-7410; e-mail: dr.shanavag@mail.ru

Michail S. Mosoyan, Dr. Sci. (Med.), Head of the Department of Urology with the Course of Robotic Surgery, Head of the Center for Robotic Surgery; Scopus: 57041359200; eLibrary SPIN: 5716-9089; e-mail: moso3@yandex.ru

Artur M. Grabsky, Dr. Sci. (Med), Associate Professor of the Department of Urology; Head of the Urology Clinic; ORCID: <https://orcid.org/0000-0001-9617-9073>; e-mail: amgrabsky@gmail.com

Karen G. Arzumanyan, clinical resident; e-mail: dr.karen.arzumanyan@gmail.com

* Corresponding author / Автор, ответственный за переписку

ОБ АВТОРАХ

***Гоча Шахиевич Шанава**, канд. мед. наук, врач-уролог; адрес: Россия, 192242, Санкт-Петербург, Будапештская ул., д. 3; eLibrary SPIN: 1706-7410; e-mail: dr.shanavag@mail.ru

Михаил Семенович Мосоян, д-р мед. наук, заведующий кафедрой урологии с курсом роботической хирургии, руководитель Центра роботической хирургии; Scopus: 57041359200; eLibrary SPIN: 5716-9089; e-mail: moso3@yandex.ru

Артур Мкртычевич Грабский, д-р мед. наук, доцент кафедры урологии, руководитель клиники урологии; ORCID: <https://orcid.org/0000-0001-9617-9073>; e-mail: amgrabsky@gmail.com

Карен Гагикович Арзуманян, клинический ординатор; e-mail: dr.karen.arzumanyan@gmail.com