

URETHRAL EROSION DEVELOPED AFTER IMPLANTATION OF ARTIFICIAL URINARY SPHINCTER

© P.S. Kyzlasov¹, A.T. Mustafayev¹, D.V. Kazantsev¹, E.V. Volokitin²

¹ State Research Center – Burnasyan Federal Medical Biophysical Center of Federal Medical Biological Agency of Russia, Moscow, Russia;

² Podgorbunsky Kuzbass Clinical Hospital of Emergency Medical Care, Kemerovo, Russia

For citation: Kyzlasov PS, Mustafayev AT, Kazantsev DV, Volokitin EV. Urethral erosion developed after implantation of artificial urinary sphincter. *Urology reports (St. Petersburg)*. 2020;10(4):361-363. <https://doi.org/10.17816/uroved48569>

Received: 26.10.2020

Revised: 05.12.2020

Accepted: 23.12.2020

⊗ The case report presents a clinical observation of urethral erosion that developed after a long-term presence of a urethral catheter in a patient after implantation of an artificial bladder sphincter. The stages of the patient's surgical treatment are described. The frequency of such complications in patients with an established artificial bladder sphincter according to literature data is presented.

⊗ **Keywords:** artificial urinary sphincter; urethral erosion; complications.

ЭРОЗИЯ УРЕТРЫ, РАЗВИВШАЯСЯ ПОСЛЕ ИМПЛАНТАЦИИ ИСКУССТВЕННОГО СФИНКТЕРА МОЧЕВОГО ПУЗЫРЯ

© П.С. Кызласов¹, А.Т. Мустафаев¹, Д.В. Казанцев¹, Е.В. Волокитин²

¹ Федеральное государственное бюджетное учреждение «Государственный научный центр Российской Федерации — Федеральный медицинский биофизический центр им. А.И. Бурназяна» Федерального медико-биологического агентства Российской Федерации, Москва;

² Государственное автономное учреждение здравоохранения «Кузбасская клиническая больница скорой медицинской помощи им. М.А. Подгорбунского», Кемерово

Для цитирования: Кызласов П.С., Мустафаев А.Т., Казанцев Д.В., Волокитин Е.В. Эрозия уретры, развившаяся после имплантации искусственного сфинктера мочевого пузыря // Урологические ведомости. – 2020. – Т. 10. – № 4. – С. 361–363. <https://doi.org/10.17816/uroved48569>

Поступила: 26.10.2020

Одобрена: 05.12.2020

Принята к печати: 23.12.2020

⊗ Представлено клиническое наблюдение эрозии уретры, развившейся после длительного нахождения уретрального катетера, у пациента после имплантации искусственного сфинктера мочевого пузыря. Описаны этапы хирургического лечения. Приведена частота подобных осложнений у пациентов с установленным искусственным сфинктером мочевого пузыря по данным литературы.

⊗ **Ключевые слова:** искусственный сфинктер мочевого пузыря; эрозия уретры; осложнения.

An implantable device used for the treatment of moderate to severe urinary incontinence is the artificial urinary sphincter (AUS). Complications are relatively rare in the early postoperative period following AUS implantation. According to various authors, however, in the long-term period, 1–2 years after surgery, their frequency is 16%–31% [1–5]. The latter can be caused by failure of the implant tightness, erosion or pressure ulcer of the urethra, as well as periprosthetic infection. In the scientific literature, the largest number of cases is presented by researchers from the Mayo Clinic (USA), who implanted AUS in 1802 men with urinary incontinence from 1983 to 2011, including primary AUS in 1082 patients [6]. In

63 (5.8%) of them, a complication in the form of erosion of the urethra was noted, which developed most often during year 1 after the intervention. All cases of urethral erosion were confirmed by urethroscopy.

In another study presented, erosion of the urethra was registered 2 years after the surgery in 1 out of 40 patients who underwent AUS [7]. There is no explanation of the development of urethral erosion later than 2 years after AUS implantation in the available literature. In the case of erosion or a pressure ulcer of the urethra, there is a high risk of urethral stricture formation. If urethral erosion is observed in patients with established AUS, removal of urine diversion device is recommended [8].

This clinical case presents the surgical treatment of a patient with urethral erosion that occurred 4 years after AUS implantation with prolonged catheterization of the bladder.

Patient Sh., 70 years of age, was admitted to the Urology Department of the Center of Urology and Andrology of the State Scientific Center of the Russian Federation, A.I. Burnazyan Federal Medical Biophysical Center of the Federal Medical-Biological Agency of Russia, in September 2020 with complaints of orthostatic urinary incontinence and purulent discharge from the perineum. In 2014, the patient was diagnosed with prostate cancer T2N0M0, and a radical retropubic prostatectomy was performed. Eventually, the patient had total urinary incontinence. In 2015, he had bladder neck stenosis; and transurethral resection of the bladder neck was carried out. A month later, a relapse of stenosis was noted; excision of the narrowed section of the urethra and urethrocytic anastomosis was performed. Further, there was an uneventful postoperative period; total urinary incontinence was noted. In 2016, an artificial bladder sphincter was implanted for urinary incontinence. Until 2020, he had no complaints of urinary incontinence, and no recurrence of prostate cancer was noted. In 2020, a neoplasm of the right iliac region was found in the patient, so surgery was performed with ureterocutaneostomy in the form of removal of the neoplasm of the right iliac region (neoplasm with invasion into the right ureter). Subsequently, laparoscopic intestinal plastic of the right ureter was performed to restore the patency of the ureter. During the postoperative period, a 14Ch Foley catheter was inserted in the patient for 2 days, due to the occlusion of the uterine catheter with mucus (intestinal discharge from the neoureter), and later on the catheter was replaced by a catheter with a larger diameter of 18Ch, the latter being removed on day 5. After 7 days, the patient noted orthostatic

urinary incontinence and purulent discharge from the perineum. In order to make the urethra freely passable up to the membranous section (the area of the artificial sphincter cuff), urethrocytoscopy was performed to deactivate the cuff. When examining the urethra in the cuff area, two defects of the urethral wall were noted at 3 and 7 o'clock position, which was an erosion of the urethra, and the cuff of the artificial sphincter was visible in the lumen of the defect. Furthermore, a decision on the surgical treatment of urethral erosion was made.

Under spinal anesthesia, a longitudinal incision in the perineum was made. In the area of the bulbo-membranous urethra, pronounced cicatricial changes were noted, which formed an infiltrate with the involvement of the urethra with a length of 4.5 cm (Fig. 1). Moreover, the urethra was mobilized using the AUS cuff with great technical difficulties and entirely by sharp dissection (Fig. 2). The presence of cicatricial cords of the spongy body, which were intimately fused with the *musculus ischiocavernosus*, is noteworthy. The cuff was removed, and the system was preserved.

At 3 and 7 o'clock position, urethra defects of about 1.0 cm in length were revealed. Moreover, a 14Ch urethral catheter was passed into the bladder through the urethra, and the urethral defect was sutured with a two-layer continuous suture (Monosyn 5/0) (Figs. 3 and 4). Additional sealing was made with surrounding tissues. In addition, safety drainage was placed in the wound. Layer-by-layer suturing was also performed (Polysorb 4/0) and an aseptic dressing was applied.

The postoperative period had no complications.

After AUS implantation, long-term complications are relatively rare and typically occur within 1 year after surgery. Subsequent complications are most often associated with iatrogenic causes. In order to prevent the development of erosions and pres-

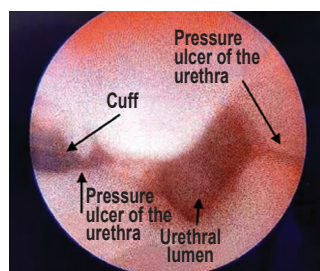


Fig. 1. Uretroscopy. Urethral erosion
Рис. 1. Уретроскопия. Эрозия уретры

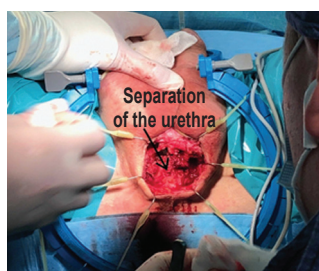


Fig. 2. Separation of the urethra from surrounding tissue
Рис. 2. Выделение уретры из окружающих тканей

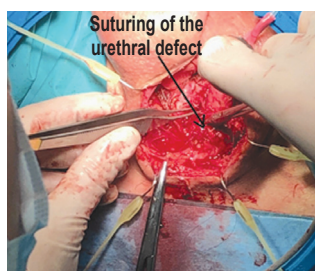


Fig. 3. Suturing of the urethral defect
Рис. 3. Ушивание дефекта уретры

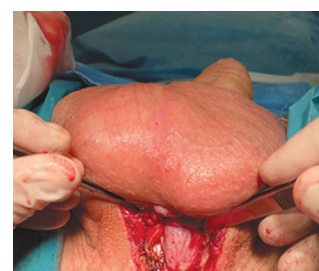

Fig. 4. View of the surgical wound after suturing of the urethral defect
Рис. 4. Вид операционной раны после ушивания дефекта уретры

sure ulcers of the urethra, the installation of AUS must be closely monitored to prevent excessive cuff pressure on the urethral wall, to limit the duration of the urethral catheter in the urethra, and to monitor this category of patients in specialized centers.

REFERENCES

1. Leibovich BC, Barrett DM. Use of the artificial urinary sphincter in men and women. *World J Urol.* 1997;15(5):316-319. <https://doi.org/10.1007/BF02202018>.
2. Elliott DS, Barrett DM. Mayo Clinic long-term analysis of the functional durability of the AMS800 artificial urinary sphincter: a review of 323 cases. *J Urol.* 1998;159(4):1206-1208.
3. Gousse AE, Madjar S, Lambert MM, Fishman IJ. Artificial urinary sphincter for post-radical prostatectomy urinary incontinence: long-term subjective results. *J Urol.* 2001;166(5):1755-1758.
4. Raj GV, Peterson AC, Toh KL, Webster GD. Outcomes following revisions and secondary implantation of the artificial urinary sphincter. *J Urol.* 2005;173(4):1242-1245. <https://doi.org/10.1097/01.ju.0000152315.91444.d0>.
5. Lai HH, Hsu EI, Teh BS, et al. 13 years of experience with artificial urinary sphincter implantation at Baylor College of Medicine. *J Urol.* 2007;177(3):1021-1025. <https://doi.org/10.1016/j.juro.2006.10.062>.
6. Agarwal DK, Linder BJ, Elliott DS. Artificial urinary sphincter urethral erosions: Temporal patterns, management, and incidence of preventable erosions. *Indian J Urol.* 2017;33(1):26-29. <https://doi.org/10.4103/0970-1591.195758>.
7. Jamaer C, De Bruyn H, Van Renterghem A, et al. Penoscrotal Incision for the Primary Implantation of an Artificial Urinary Sphincter. *Curr Urol.* 2020;14(2):74-78. <https://doi.org/10.1159/000499256>.

Information about the authors:

Pavel S. Kyzlasov — Dr. Sci. (Med.), Professor of Department Urology and Andrology of Medical and Biological University of Innovation and Continuing Education, Head of Center of Urology and Andrology. State Research Center — Burnasyan Federal Medical Biophysical Center of Federal Medical Biological Agency of Russia, Moscow, Russia. E-mail: dr.kyzlasov@mail.ru.

Ali T. Mustafayev — Postgraduate, Department Urology and Andrology of Medical and Biological University of Innovation and Continuing Education. State Research Center — Burnasyan Federal Medical Biophysical Center of Federal Medical Biological Agency of Russia, Moscow, Russia. E-mail: dr.mustafayevat@gmail.com.

Daniil V. Kazantsev — Clinical Resident, Department Urology and Andrology of Medical and Biological University of Innovation and Continuing Education. State Research Center — Burnasyan Federal Medical Biophysical Center of Federal Medical Biological Agency of Russia, Moscow, Russia. E-mail: kazancev_daniil@mail.ru.

Evgenii V. Volokitin — Urologist, Urological Division. Podgorbunsky Kuzbass Clinical Hospital of Emergency Medical care, Kemerovo, Russia. E-mail: evgvolokitin82@mail.ru.

Сведения об авторах:

Павел Сергеевич Кызласов — д-р мед. наук, профессор кафедры урологии и андрологии Медико-биологического университета инноваций и непрерывного образования, руководитель Центра урологии и андрологии. ФГБУ «ГНЦ РФ — ФМБЦ им. А.И. Бурназяна» ФМБА России, Москва. E-mail: dr.kyzlasov@mail.ru.

Али Тельман-оглы Мустафаев — аспирант кафедры урологии и андрологии Медико-биологического университета инноваций и непрерывного образования. ФГБУ «ГНЦ РФ — ФМБЦ им. А.И. Бурназяна» ФМБА России, Москва. E-mail: dr.mustafayevat@gmail.com.

Даниил Владиславович Казанцев — клинический ординатор кафедры урологии и андрологии Медико-биологического университета инноваций и непрерывного образования. ФГБУ «ГНЦ РФ — ФМБЦ им. А.И. Бурназяна» ФМБА России, Москва. E-mail: kazancev_daniil@mail.ru.

Евгений Викторович Волокитин — врач-уролог отделения урологии. ГАУЗ ККБСМ, Кемерово. E-mail: evgvolokitin82@mail.ru.